

the Ophthalmologist™

Upfront

Statins for
vitrectomy surgery

12

In My View

PTA for post-LASIK
ectasia: pro and con

14 - 17

In Practice

SICS - another feather
in your cap?

28 - 32

Sitting Down With

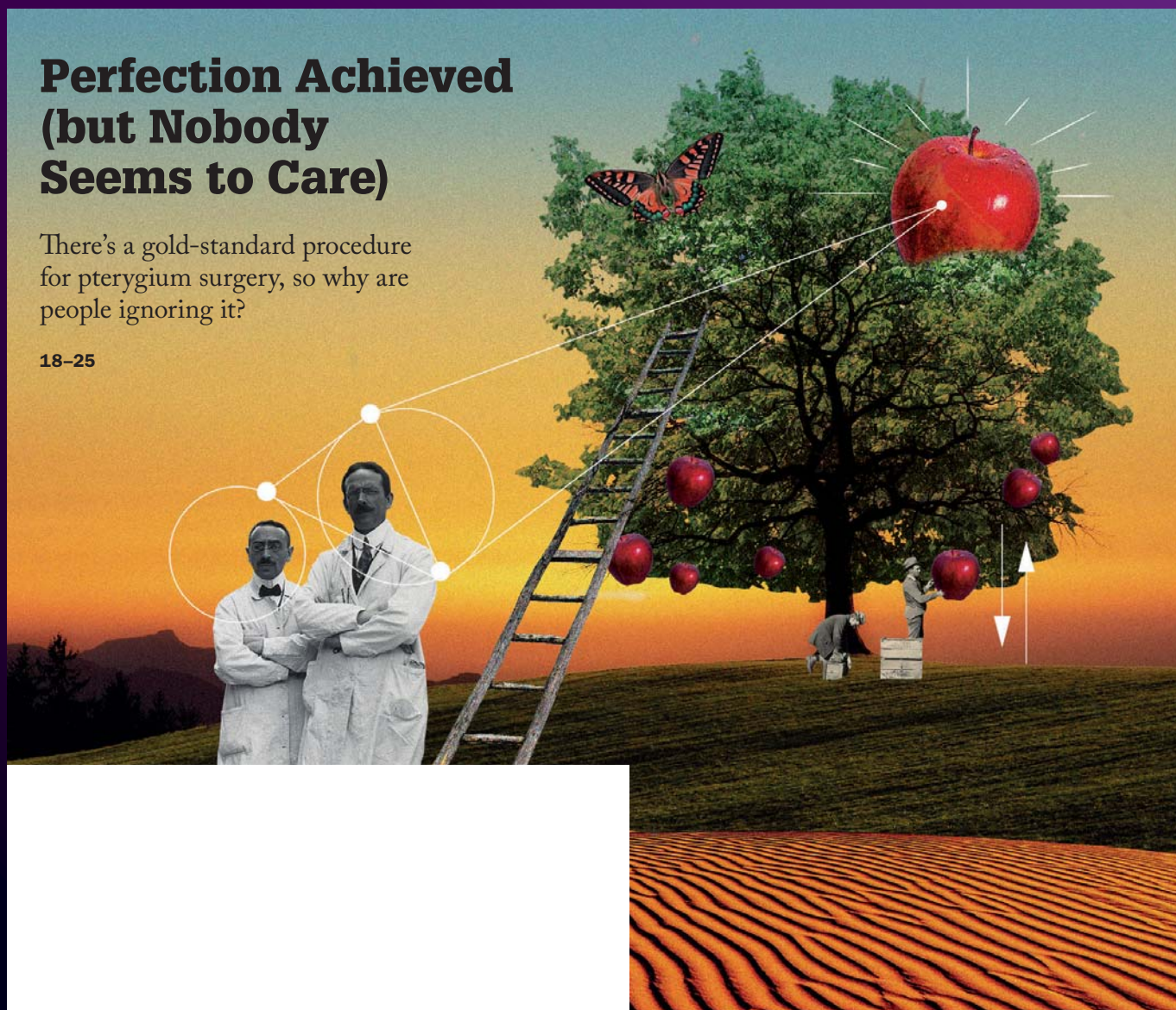Walter Sekundo,
a.k.a., Mr. SMILE

48 - 50

Perfection Achieved (but Nobody Seems to Care)

There's a gold-standard procedure
for pterygium surgery, so why are
people ignoring it?

18-25



100 MILLION MOMENTS MADE.

100
MILLION
IMPLANTED WORLDWIDE
Only
with AcrySof®



Thanks to you, AcrySof® IOLs have created
more memories than any other lens.

Over the last 25 years, the AcrySof® portfolio of monofocal, toric and multifocal IOLs has been chosen with confidence.
Ask your Alcon representative what makes AcrySof® the most implanted lens in the world*.

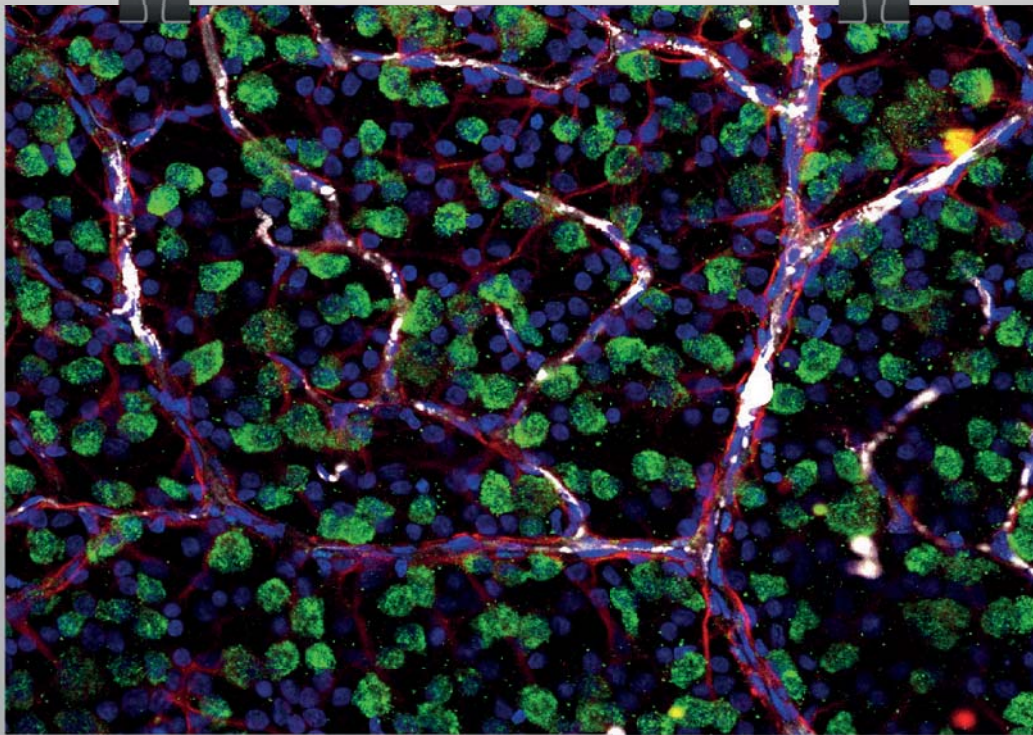
* Alcon data on file.

Alcon A Novartis
Division

 AcrySof® IQ IOL Family

 **Advancing**
CATARACT SURGERY

Image of the Month



The Astrocyte Fight Against Glaucoma

This confocal microscopy image features the delicate neurovascular plexus of the inner retina, and shows retinal ganglion cells (green), astrocytes (red) and vascular endothelial cells (white) in the inner retina of a rat. This image was taken in the Sivak lab at the Krembil Research Institute, University Health Network and University of Toronto School of Medicine, Canada, and forms part of multi-center research project that has identified that lipoxins – lipid inflammatory mediators – secreted by astrocytes can protect against retinal ganglion cell degeneration in rodent models of glaucoma.

I Livne-Bar et al., J Clin Invest, [Epub ahead of print], (2017). PMID: 29106385. Credit: Xiaxin Guo and Jeremy Sivak.

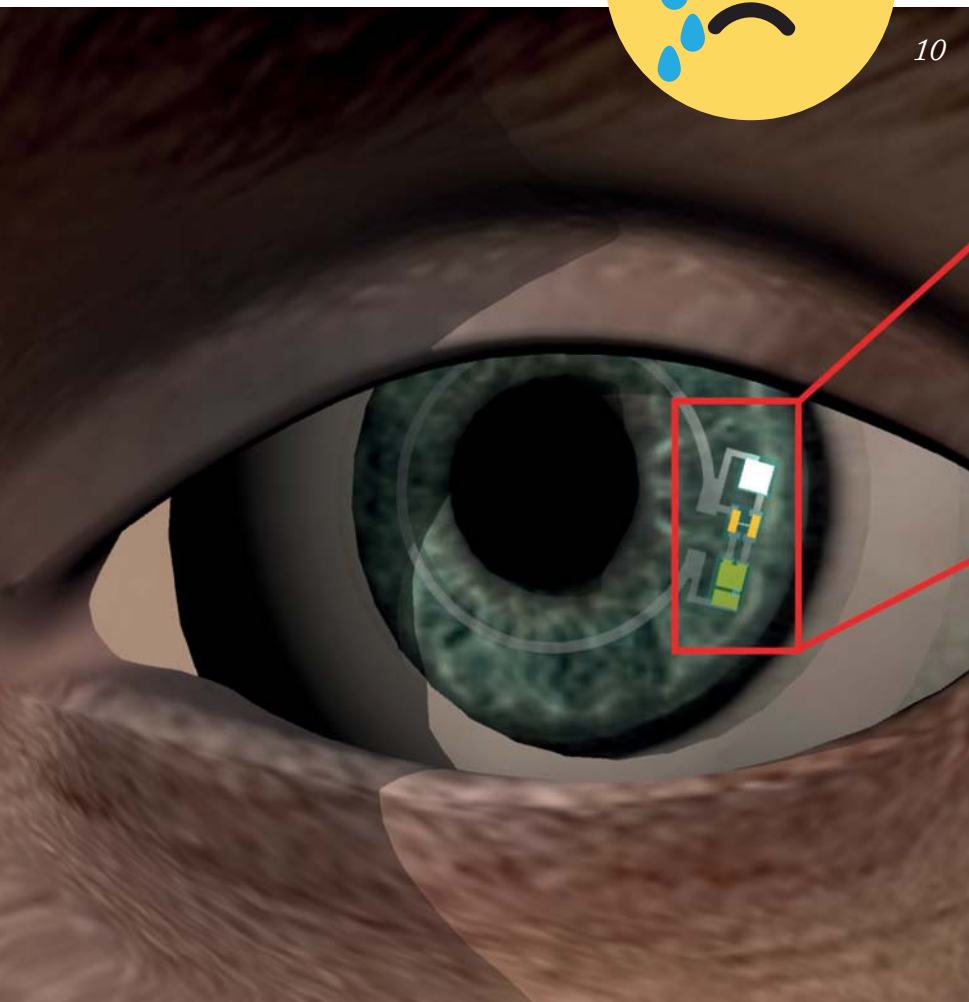
Do you have an image you'd like to see featured in The Ophthalmologist?
Contact edit@theophthalmologist.com



Contents



10



03 Image of The Month

09 Editorial Dangerous Déjà Vu... by Ruth Steer.

On The Cover



Doctors picking the low-hanging fruit, but avoiding the approach to the true gold-standard at the top of the tree.

Upfront

- 10 Sweet Tears
- 11 Night Guard
- 11 The Ophthalmologist Power List Returns for 2018
- 12 Reducing Revitrectomy Risk
- 13 Central Corneal Connection

the Ophthalmologist

ISSUE 18 - FEBRUARY 2018

Editor - Mark Hillen
mark.hillen@texerepublishing.com

Managing Editor - Ruth Steer
ruth.steer@texerepublishing.com

Content Director - Rich Whitworth
rich.whitworth@texerepublishing.com

Publishing Director - Neil Hanley
neil.hanley@texerepublishing.com

VP Sales North America - Molly Phillips
molly.phillips@texerepublishing.com

Sales Manager - Abigail Mackrill
abigail.mackrill@texerepublishing.com

Head of Design - Marc Bird
marc.bird@texerepublishing.com

Designer - Hannah Ennis
hannah.ennis@texerepublishing.com

Digital Team Lead - David Roberts
david.roberts@texerepublishing.com

Digital Producer Web/Email - Peter Bartley
peter.bartley@texerepublishing.com

Digital Producer Web/App - Abygail Bradley
abygail.bradley@texerepublishing.com

Audience Insight Manager - Tracey Nicholls
tracey.nicholls@texerepublishing.com

Traffic & Audience Database Coordinator - Hayley Atiz
hayley.atiz@texerepublishing.com

Traffic and Audience Associate - Lindsey Vickers
lindsey.vickers@texerepublishing.com

Traffic Manager - Jody Fryett
jody.fryett@texerepublishing.com

Social Media / Analytics Associate - Ben Holah
ben.holah@texerepublishing.com

Events Manager - Alice Daniels-Wright
alice.danielswright@texerepublishing.com

Marketing Manager - Katy Pearson
katy.pearson@texerepublishing.com

Financial Controller - Phil Dale
phil.dale@texerepublishing.com

Accounts Assistant - Kerri Benson
kerri.benson@texerepublishing.com

Editorial Director - Fedra Pavlou
fedra.pavlou@texerepublishing.com

Chief Executive Officer - Andy Davies
andy.davies@texerepublishing.com

Chief Operating Officer - Tracey Peers
tracey.peers@texerepublishing.com

Change of address
hayley.atiz@texerepublishing.com
Hayley Atiz, The Ophthalmologist,
Texere Publishing Ltd, Haig House, Haig Road,
Knutsford, Cheshire, WA16 8DX, UK

General enquiries
www.texerepublishing.com
info@texerepublishing.com
+44 (0) 1565 745 200
sales@texerepublishing.com

Distribution
The Ophthalmologist (ISSN 2051-4093)
and The Ophthalmologist North America
(ISSN 2398-9270), is published monthly by
Texere Publishing Ltd and is distributed in the
US by UKP Worldwide, 3390 Rand Road,
South Plainfield, NJ 07080.
Periodicals postage paid at South Plainfield, NJ
and additional mailing offices.
POSTMASTER: Send US address changes to
The Ophthalmologist C/O 3390 Rand Road,
South Plainfield NJ 07080.
Single copy sales £15/\$20
(plus postage, cost available on request
tracey.nicholls@texerepublishing.com)
Annual subscription for non-qualified
recipients £110/\$140

Reprints & Permissions - tracey.nicholls@texerepublishing.com
The opinions presented within this publication are those of the authors
and do not reflect the opinions of The Ophthalmologist or its publishers,
Texere Publishing. Authors are required to disclose any relevant financial
arrangements, which are presented at the end of each article, where relevant.
© 2017 Texere Publishing Limited. All rights reserved.
Reproduction in whole or in parts is prohibited.



Partners



TRS-5100
Product/Model name:
REFRACTOR RT-5100

The **TRS-5100** offers a split prism Jackson Cross cylinder with simultaneous target comparisons, for faster, more accurate and more positive exam experiences. Maximize exam efficiency, patient flow, and overall practice revenue.

AND DESIRED OUTCOMES



Mitchell A. Jackson, MD
Lake Villa, Illinois

The TRS-5100 rapidly completes all refractions and the split prism allows immediate patient comparison and verification of old vs. new prescriptions – without flipping through lenses and asking “which is better, 1 or 2?”



Larry Patterson, MD
Crossville, TN

The TRS-5100 takes accuracy to a new level and provides the ultimate refraction information that we’ve been seeking. Now, we have fewer remakes with more satisfied patients who enjoy shorter refraction exam times.



Charles Collins, MD
Middleton, RI

The TRS-5100 is highly valued. It is extremely accurate and I’m very confident in the quality of refraction. It is such a timesaver, has cut down on remakes, reduced our frustrations and increased our bottom line.



Faisal Haq, MD
Plano, Texas

The TRS provides our practice with a diagnostic tool that both improves clinical outcomes while increasing patient flow and overall efficiency. The investment that pays for itself. Wait times are reduced, we see more patients, and we’re performing more surgery than ever.



Designed and Manufactured by NIDEK - Represented by Marco
800-874-5274 • marco.com



ZEPTO™

PRECISION PULSE CAPSULOTOMY



EXPERIENCE ZEPTO™ ASSISTED CATARACT SURGERY

Precise, visually centered, and stronger
capsulotomies in milliseconds

The perfect capsulotomy – one less variable in refractive predictability

ZEPTO™ is a novel capsulotomy device with a disposable handpiece and tip that produces fast, consistent, elegant, high quality capsulotomies at your fingertips. Use with confidence in challenging cases and with premium IOLs in your practice. The tip consists of a miniature, transparent, soft silicone suction cup that houses a circular nitinol capsulotomy element. Refined at the micron scale to enable uniform 360-degree capsule cutting, ZEPTO™ allows intraoperative capsulotomy centration on the patient's visual axis for an optimized outcome.

Mynosys

www.mynosys.com



To order ZEPTO™ - eMail: order@precisionlens.net • 800-514-1095 • Fax: 952-881-2453 • www.precisionlens.net



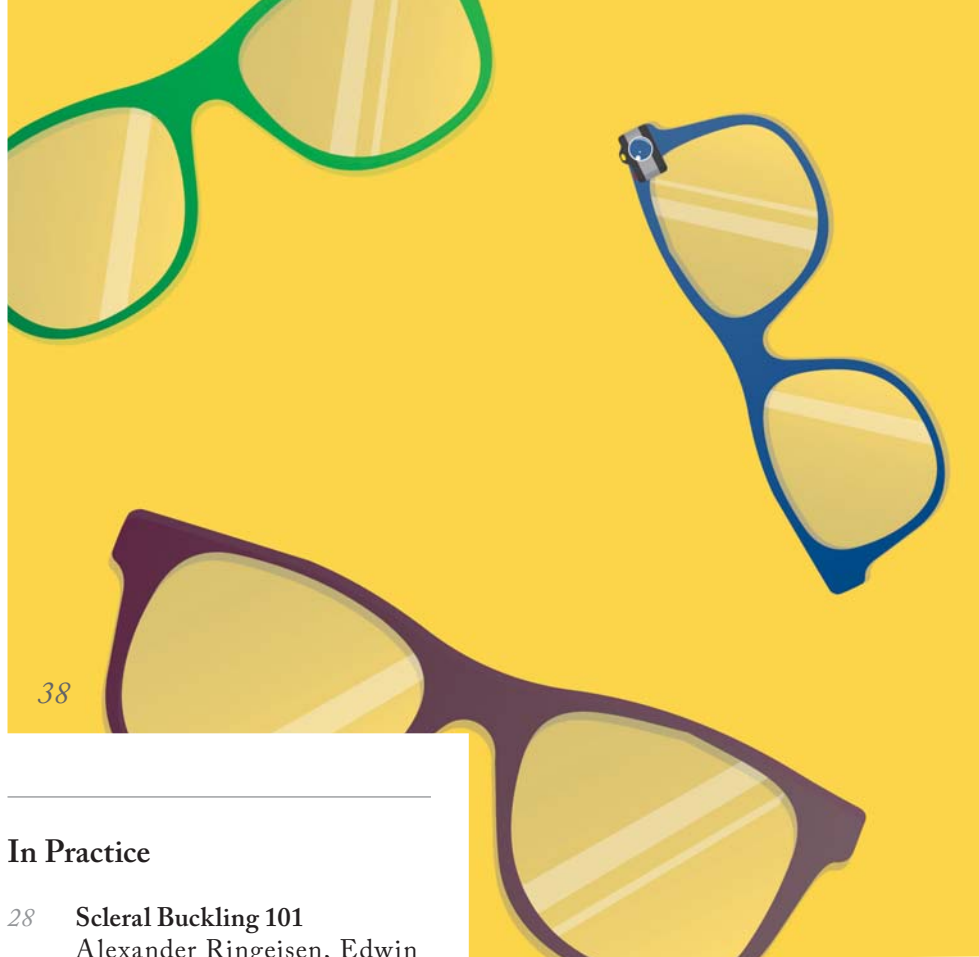


In My View

- 14 Playing Our Cards Right,
by **Marcony Santhiago**
- 15 PTA Is Not the Way,
by **Alain Saad**
- 17 The Anti-Social Network,
by **Martine Jager**

Feature

- 18 **Perfection Achieved (But Nobody Seems to Care)**
There's a clear gold standard in pterygium removal that gives almost perfect outcomes with almost no recurrence... but there's also a quick and dirty fix. Guess which one most people choose to perform.



In Practice

- 28 **Scleral Buckling 101**
Alexander Ringeisen, Edwin Ryan and David Almeida review the occasions when scleral buckling should be considered – and how to succeed.
- 33 **A Small Solution to a Significant Problem**
M. Scott Hickman explains what small incision cataract surgery (SICS) is, plus how to do it – and when to use it.

NextGen

- 38 **Making the Subjective Objective**
How off the shelf electronics components are being combined in a smart device that should enable cataract and refractive surgeons to stop relying on chair time and questionnaires to understand their lifestyle and vision needsneeds – and use hard data instead.

Profession

- 44 **Is Twitter Dead?**
Pavan Angadi and Robert F. Melendez examine how ophthalmologists use Twitter and offer their advice on getting the most out of social media.
- 46 **Decision Diagnosis**
Procrastination is the first step on the path towards the calamity of inaction. David Almeida shows how he approaches problems by taking a “Decision Diagnosis” approach.

Sitting Down With

- 48 **Walter Sekundo**, Chairman of the Department of Ophthalmology, Philipps University of Marburg, Germany.

OCuSOFT®

**OLDIE
BUT A
GOODIE**

SINCE 1986



**OCuSOFT®
LID SCRUB®**



Some things are just too good to change. OCuSOFT® Lid Scrub® Family of Eyelid Cleansers includes mild, non-irritating cleansers that effectively remove contaminants from the eyelids to provide relief of symptoms associated with conditions ranging from mild to severe. Trusted and recommended by optometrists and ophthalmologists, OCuSOFT® is still the leading brand of eyelid cleansers on the market. It's trusted. It works.

#1 Doctor Recommended Brand

(800) 233-5469 | www.ocusoft.com

© 2017 OCuSOFT, Inc., Rosenberg, TX 77471



In early 2017, I was shocked – along with the rest of the world – to hear that three AMD patients had suffered permanent vision loss after receiving an unapproved stem cell therapy at a clinic in Florida (1). Disturbingly, the story got murkier: the patients had paid \$5,000 each to receive the autologous-derived stem cell injections (AASCIIs). And despite a clinical trial being registered at the clinic (NCT02024269; withdrawn in September 2015 – three months after the experimental ‘treatments’), none of the patients actually knew that they were participants. Further investigative journalism revealed that two of the physicians on the approving ethical board had troubled disciplinary histories (2).

At the beginning of 2018, I was even more shocked to discover that the above incident was not isolated. In a case report published in the January issue of JAMA Ophthalmology, Andrew Rong and colleagues described a male patient who presented with poor visual acuity (hand motion in the right eye and 20/30 in the left eye), and a pupillary defect and extensive proliferative vitreoretinopathy in the right eye (3). Six months prior, the patient had received AASCIIs for retinitis pigmentosa – and paid \$4,000 for the privilege. Lured to a stem cell clinic in Florida by a television commercial, the patient had been referred to an office in the Dominican Republic for the ‘treatment’, but received no follow-up care despite experiencing visual problems. It had happened again – and it wasn’t the only case described.

It’s been playing on my mind ever since. Could this be a growing problem in the US with more patients at risk? Rong certainly thinks so, blaming the rise of profiteering stem cell clinics who peddle promising research rather than proven therapies. The fact that autologous cell procedures sit in a regulatory ‘gray area’ depending on how they’re prepared also plays a role – especially when unscrupulous individuals seek to evade oversight by downplaying the extent to which the cells are manipulated.

So who is ultimately responsible for protecting these sometimes-desperate patients? Do ophthalmologists need to shout louder or should regulatory agencies take charge? It seems to me that an ‘all hands on deck’ approach might be the best way to tackle the rising tide – not only to save sight but also to preserve public trust in stem cell therapies of the future.

References

1. AE Kuriyan et al., “Vision loss after intravitreal injection of autologous ‘stem cells’ for AMD”, *N Engl J Med*, 376, 1047–1053 (2017). PMID: 28296617.
2. P Aldhous, *BuzzFeed News* (2017). “An experiment that blinded three women unearths the murky world of stem cell clinics”, Available at: bit.ly/AldhousBuzz. Accessed January 25, 2018.
3. AJ Rong et al., “Vision loss secondary to autologous adipose stem cell injections: a rising problem”, *JAMA Ophthalmol*, 136, 97–99 (2018). PMID: 29192301.

Ruth Steer
Managing Editor

Upfront

Reporting on the innovations in medicine and surgery, the research policies and personalities that shape the practice of ophthalmology.

We welcome suggestions on anything that's impactful on ophthalmology; please email edit@theophthalmologist.com

Sweet Tears

A noninvasive method to monitor disease in the eye

Many people with diabetes would be happy to see the back of their blood glucose monitor and daily finger-prick tests. Enter: a team of scientists from the Ulsan National Institute of Science and Technology (UNIST), South Korea, who have created a means of wirelessly monitoring glucose levels with a soft contact lens.

“Embedded within our smart contact lens are electronic circuits, an antenna, a glucose sensor and LED pixels integrated as stretchable forms,” explains Jang-Ung Park (1). “This improves the comfort and wearing-time of the lens compared with previous smart lenses that were hard due to having brittle and more rigid components.”

Their sensor comprises a graphene surface to which glucose oxidase (GOD) enzyme is immobilized. Tears (containing glucose) pass through the sensor channel; GOD oxidizes the

glucose, which releases electrons in a concentration-dependent manner, which the sensor detects, enabling the glucose concentration to be determined (1). The sensor contains an LED that responds to the changes in resistance (which is coupled to tear glucose concentration). Below 0.9 mM, the LED emits light; above this, the LED pixel is turned off, providing a visible cue that the glucose threshold has been reached (Figure 1).

So far, the team has demonstrated that the device can respond to changing glucose concentrations in rabbit eyes, and they plan to move into clinical tests in humans. But what of its applications for ophthalmology? The team write that their novel system could “provide a platform for wireless, continuous, and noninvasive monitoring of physiological conditions, as well as the detection of biomarkers associated with ocular and other diseases,” – and drug delivery isn’t out of the question.

Reference

1. J Park et al., “Soft, smart contact lenses with integrations of wireless circuits, glucose sensors, and displays”, *Science Advances*, 4, aap9841 (2018).

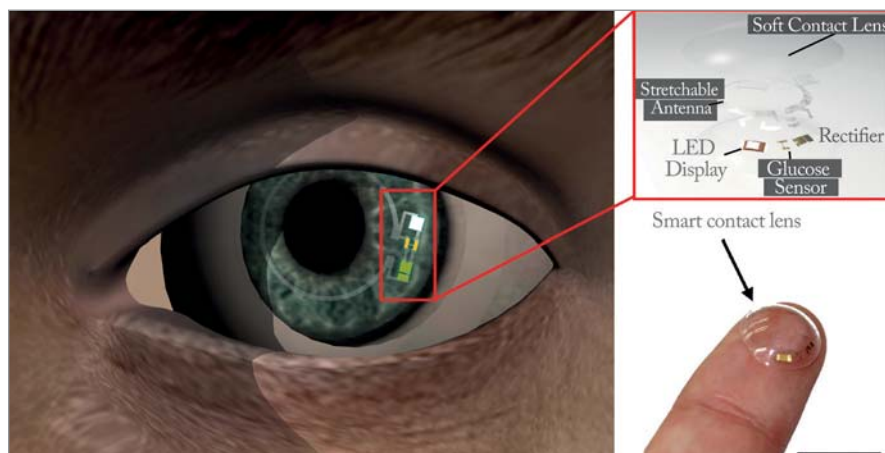


Figure 1. The soft, smart contact lens is comprised of a hybrid substrate, functional devices (rectifier, LED and glucose sensor) and a transparent, stretchable conductor (for antenna and interconnects). Electric power is wirelessly transmitted to the lens through the antenna, and activates the LED pixel and the glucose sensor. If glucose levels in tear fluid above the predefined threshold level (0.9 mM), the pixel turns off (1).

Night Guard

New research reveals how pupils behave when we are asleep

It's well understood that pupil size can be dictated by surrounding light conditions and attentional states during wakefulness, but how do pupils behave during sleep? A research group from the University of Geneva in Switzerland had recently observed that their laboratory mice often slept with their eyes open under certain conditions and decided to study how pupil dynamics evolve during sleep. They found that pupil size changed rhythmically when the mice were asleep (Figure 1), and corresponded with sleep states (NREM and REM) (1). Hypothesizing that pupil size varies during sleep to protect the eyes from light stimulus that might interrupt slumber, the authors plan to pursue their studies in humans. Corresponding author, Daniel Huber, tells us more...

How did you track pupil behavior?

For this study, we developed a novel optical pupil tracking system for mice in which an infrared LED was apposed to the head of the animal. The invisible light from this LED travels through the skull and brain, and finally illuminates the back of the eye. When the eyes were imaged with an infrared camera, the pupils appeared as bright

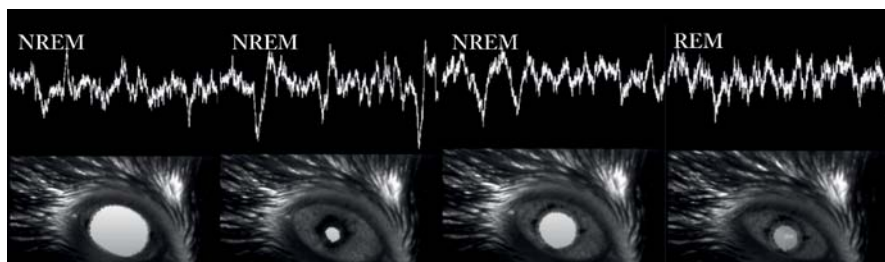


Figure 1. Video stills displaying infrared back-illumination pupillometry (iBip) pupil tracking and corresponding electrocorticogram of a sleeping mouse during periods of NREM and REM. Credit: Özge Yüzgeç, Mario Prsa, Robert Zimmermann, Daniel Huber. NREM, non-rapid eye movement; REM, rapid eye movement.

circles. This novel illumination method was easy to implement, it tracked the pupil accurately and facilitated tracking even under conditions where the eyelid is partly closed.

Any surprising results?

We were stunned by the strong coupling between brain activity and pupil size. This correlation was found to be much greater than the one previously described during the awake state. We also expected this was a passive phenomenon due to the well-known decrease in sympathetic drive during sleep, but to our surprise, these fluctuations were uniquely mediated by active parasympathetic control. This near-monopoly of the parasympathetic pathway in NREM sleep might be unique to mice, given the difference in their physiology. In humans, the regulation might be a bit more complex. This will be part of future research.

What modifications will you need for future human studies?

We are thinking about adapting our current method by developing a novel pair of wearable pupil tracking goggles which would determine the depth of sleep based on the pupil dynamics.

Do you predict the same results in humans?

Yes – humans and mice show very similar dynamics in general sleep patterns. However, there might be differences by which sleep is regulated in both species. We are currently talking to sleep laboratories and discussing how to study similar phenomena in humans. Patients sleeping naturally with their eyelids open (nocturnal lagophthalmos) might give us our first insights very soon.

Reference

1. Ö Yüzgeç et al., "Pupil size coupling to cortical states protects the stability of deep sleep via sympathetic modulation", *Curr Biol*, pii: S0960-9822(17)31682-2 (2018). PMID: 29358069.

The Ophthalmologist Power List Returns for 2018

Who are the 100 most influential people in ophthalmology today?

Every April, The Ophthalmologist features its annual celebration of ophthalmology: the Power List. Last year, we asked you, our readers, to nominate the early stage clinicians who are going to shape the future field of eyecare. From hundreds of nominations, our expert judging panel assembled the top 50 Rising Stars, with Alex Huang hoisted to the very top for his pioneering work on aqueous angiography.

For 2018, we return to celebrating the top

100 most influential people in ophthalmology. Clinicians, scientists, industry personalities, and leaders of the field are all eligible for nomination. If they've made an impact on ophthalmology, we want to hear about it.

Tell us who you want to see in the list and why, using the link below. Nominations are open until February 26, 2018.

Nominate here: <http://top.txp.to/powerlist-2018-form>

Reducing Revitrectomy Risk

A Finnish study suggests that systemic statins lower the risk of revitrectomy in RRD by 28 percent

Statins are widely used for good reason. They reduce serum lipoprotein levels and treat dyslipidemias like atherosclerosis, and happen to have anti-inflammatory, anti-oxidative, anti-fibroproliferative, microvasculo-protective and neuroprotective effects too. Almost a third of the US adult population are prescribed them, and cardiologists half-joke that they should be offered as a condiment at fast-food restaurants, as they've shown great benefit in reducing cardiovascular mortality and morbidity. They have prevented (or delayed) millions of heart attacks since their introduction – and it looks like they have another trick up their sleeve: reducing the risk of revitrectomy in patients who have undergone vitrectomy for rhegmatogenous retinal detachment (RRD).

The antifibroproliferative effect of statins piqued the interest of a group of Helsinki-based doctors and researchers, who knew from the work of Jules Gonin back in 1934 about proliferative vitreoretinopathy (PVR) – the intraocular fibrosis formation that is considered to be the worst-case scenario after VR surgery and necessitates re-operation. An agent that can prevent PVR would be of great benefit, but clinical evaluations of steroids, daunorubicin, 5-fluorouracil and many anti-inflammatory and anti-VEGF agents have all failed to show a significant benefit. Could statins succeed where the others have failed? After all, rabbit studies of statins in a glaucoma filtration model suggested that they had a beneficial effect. Would this trend hold in humans undergoing VR surgery? After all,

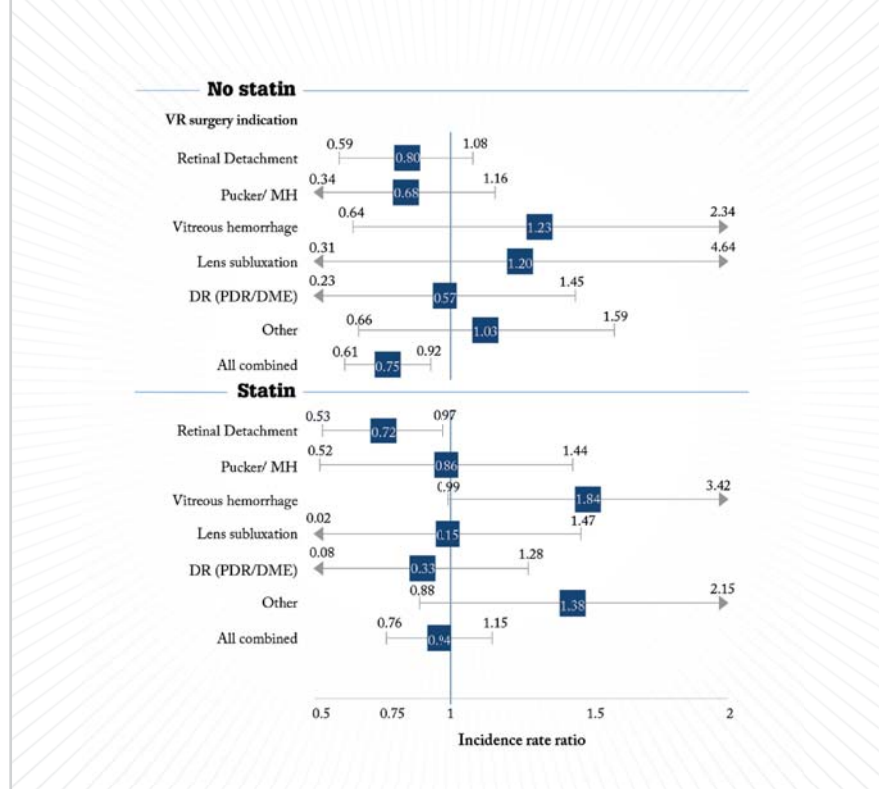


Figure 1. Multivariate models, adjusted with sex, age, duration of operation, procedure, use of insulin/ oral antidiabetic/ antithrombotic/ β -blocker drugs, and diagnosis subgroup as covariates. DME, diabetic macular edema; DR, diabetic retinopathy; MH, macular hole; PDR, proliferative DR.

many patients undergoing VR surgery will also be receiving statin therapy.

The team performed an exhaustive record review; after certain exclusion criteria were applied, the records of 5,707 patients aged ≥ 18 years who underwent vitrectomy in Helsinki University Hospital in Finland over a 6.5 year period between 2008–2014 were analyzed, including demographic variables, the type and duration of surgery, concomitant diseases, prescribed medications, and follow-up time. The primary end-point was revitrectomy during the 1-year postoperative follow-up period, due to retinal redetachment, vitreous rehemorrhage, postoperative endophthalmitis, recurrent pucker or unclosed macular hole.

They found that RRD was the second most frequent indication for VR surgery (1,916 patients; 305 reoperations) – a rate of 0.20 (95% CI 0.18–0.23) per person-year. Patients who were on statin therapy at the time of operation had a lower relative risk of re-operation (an incidence rate ratio of 0.72, 95% CI 0.53–0.97; Figure 1), but not a lower absolute risk (incidence rate difference –0.58, 95% CI –4.30 to 3.15 for 100 person-years). They found no association with statin therapy

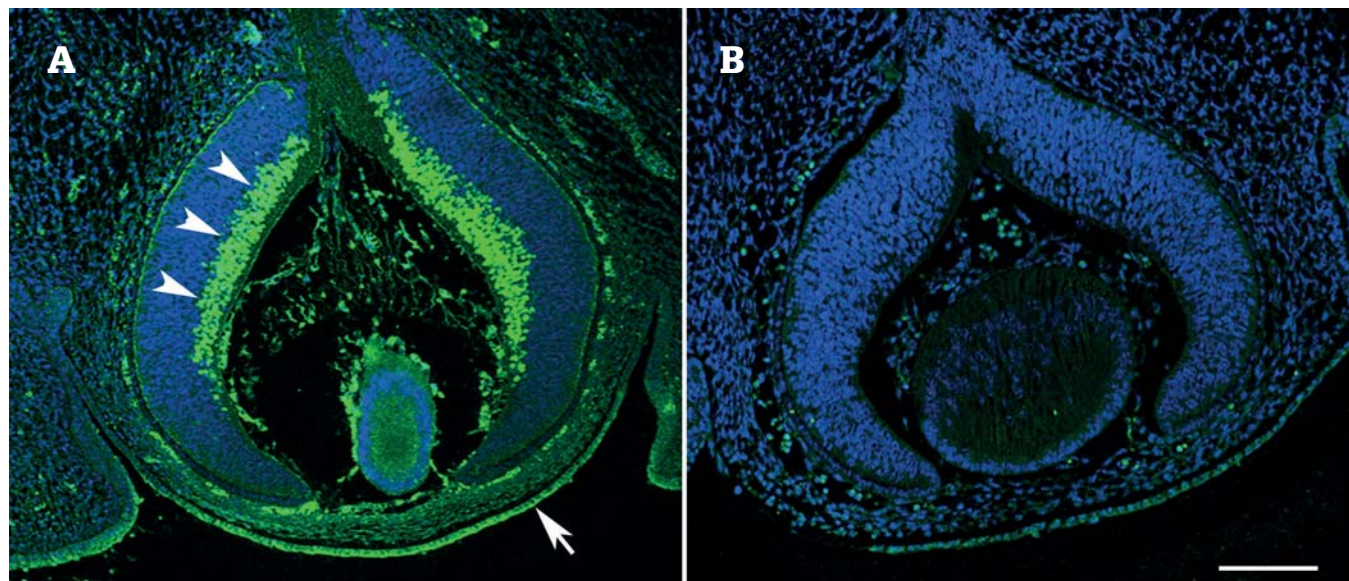
and vitrectomy in the other VR subgroups (Figure 1). When they looked further at the statins used, of the three used in their cohort (simvastatin, atorvastatin, and rosuvastatin), only simvastatin seems to be associated with the lower revitrectomy rate.

The study's authors recognize that the comparison had a number of weaknesses; it was a registry-based trial, the operations were carried out by multiple VR surgeons and there was a possibility of confounding factors connected to statin use. But they do urge that further investigation be performed – to answer questions like: what age groups should receive the statins, how could statin therapy be best used as an adjuvant to prevent re-operations after RRD surgery, and should all patients diagnosed with an RRD start statin therapy right away? Frankly, it's hard to ignore a 28 percent reduction in reoperation rates that can be achieved with a generic statin.

Reference

1. S Loukovaara et al., "Statin use and vitreoretinal surgery: Findings from a Finnish population-based cohort study", *Acta Ophthalmol*, [Epub ahead of print] (2018). PMID: 29338115.

Figure 1. POU6F2 histochemistry in the embryonic eye (postnatal day 15; (A)) and secondary antibody-only control section (B). In (A), the neuroblasts destined to become RGCs (arrow heads) and developing cornea and corneal epithelium (arrow) are stained prominently, whereas this staining is mostly absent in the control section (B). Scale bar, 100µm.



Rebecca King and colleagues

Central Corneal Connection

A genetic link between CCT and glaucoma has been identified

“What does a transcription factor expressed in the cornea have to do with glaucoma?” asks Eldon Geisert Jr, Professor of Ophthalmology at Emory Eye Center, Atlanta, Georgia, USA. Well, Geisert and his team have identified that the transcription factor in question – POU6F2 – could be a risk factor for primary open angle glaucoma (POAG) (1).

Thinner corneas are a well-known risk factor for POAG, but no one has really understood how or why, because of the multiple confounding genetic and environmental factors – and the need for extremely large sample sizes for genetic analysis. Inspired to understand more about the mechanisms of neuronal death in glaucoma, Geisert and his team set out to investigate the potential molecular link between central corneal thickness (CCT) and this process with a more feasible approach.

Using BXD RI mice (strains of fully

mapped and sequenced inbred mice that allow genetic loci to be linked to phenotype), the team measured the CCT of 818 mice from 61 members of the strain set, and used the information to identify novel quantitative trait loci (QTLs) that modulate CCT with bioinformatics data analysis tools hosted on GeneNetwork.org. Comparing the candidate genes from this analysis with human corneal and glaucoma genome-wide association (GWAS) datasets, the team identified that the top 50 hits in the POAG dataset resided in the locus for *POU6F2*.

Studying POU6F2 expression in embryonic mice, the team identified that the transcription factor was strongly expressed in neuroblasts – precursors to retinal ganglion cells (RGCs) – as well as in developing corneal endothelium and corneal stem cells (Figure 1). In adult mice, POU6F2 was strongly expressed in a subset of RGCs. The team also identified that CCT was significantly thinner in *Pou6f2*-null mice compared with wild-type littermates ($p < 0.01$), and that POU6F2-expressing RGCs were susceptible to death in a mouse model of glaucoma (1).

“As almost everyone believes that the link between CCT and glaucoma is due to the stiffness of the cornea and the sclera,

the associated genes should be associated with extracellular matrix or collagen – not a transcription factor,” says Geisert. “In our case, the results did not fit the current paradigm.” Explaining that POU6F2 has completely different roles in the different tissues of the eye, Geisert says: “In the cornea, POU6F2 is involved in development of the tissue and marks the stem cells that maintain corneal integrity; in the retina, it is part of a molecular signature that modulates the susceptibility of the RGCs to injury.”

The team believes that their identification of POU6F2 as a potential risk factor for POAG could not only provide a marker for the early detection of POAG, but also further the understanding of why some retinal cell types are particularly sensitive to injury. Geisert also hypothesizes that POU6F2 could also be a risk factor for normal tension glaucoma. “We also study ocular blast injuries for the Department of Defense, and in this model of ocular injury, the POU6F2-expressing cells appear to be the first to die.”

Reference

1. R King et al., “Genomic locus modulating corneal thickness in the mouse identifies POU6F2 as a potential risk of developing glaucoma”, *PLOS Genet*, 14: e1007145 (2018) PMID: 29370175.

In My View

In this opinion section, experts from across the world share a single strongly-held view or key idea.

Submissions are welcome. Articles should be short, focused, personal and passionate, and may deal with any aspect of ophthalmology. They can be up to 600 words in length and written in the first person.

Contact the team at edit@theophthalmologist.com

Playing Our Cards Right

Why the evidence shows that high PTA is a risk factor for post-LASIK ectasia



By Marcony Santhiago, Professor of Ophthalmology at the Federal University of Rio de Janeiro and the University of Sao Paulo, Brazil; and Adjunct Professor of Ophthalmology at the University of Southern California, Los Angeles USA.

If percentage tissue altered (PTA – the combination of the flap thickness plus the ablation depth divided by the pre-operative central corneal thickness) is high, it represents a risk factor for post-LASIK ectasia (1–6). And the higher the PTA, the higher the risk. I'd like to highlight three important points to go along with that statement: firstly, the concept of PTA comes from a solid theoretical foundation. Secondly, it is a risk factor and not a screening method. And thirdly, how risk factors are investigated is of utmost importance.

The creation of a LASIK anterior lamellar flap should not normally be associated with a significant loss in corneal biomechanical strength. However, corneal tensile strength is not uniform throughout the central cornea (posterior corneal stromal tissue is weaker than anterior stromal tissue – especially the posterior two-thirds of the cornea), meaning that the deeper the LASIK flap cut, and the greater the amount of tissue ablated, the weaker the remaining cornea becomes (7). Based on these structural differences, it is

reasonable that a ratio or equation would be representative of post-LASIK changes, specifically of values of residual stromal bed or corneal thickness. And that's why we proposed measuring PTA as a risk factor for post-LASIK corneal ectasia.

When we first started trying to determine new methods of assessing corneal biomechanics with BJ Dupps, we also looked at which intraoperative variables induced changes in these parameters. PTA was one of those investigated and, to our surprise, it had the highest number of significant correlations with changes in the biomechanical variables under assessment. As ectasia likely represents a reduction in biomechanical integrity below the threshold required to maintain corneal shape and curvature, we wanted to understand if there was an association between PTA and ectasia. We identified that PTA was significantly higher in a group of patients who developed ectasia after LASIK compared with a group of patients who hadn't developed any complications three years after surgery (2). We then proceeded to investigate ectatic patients who had normal pre-operative topography in a case-control study, and identified that PTA equal to or higher than 40 percent was by far the most prevalent risk factor, and had an odds ratio of 223 (3)!

Our case-control study was appropriately designed to investigate PTA as a risk factor – and this matters. Saad et al. (8) also investigated PTA in a retrospective cohort study of 126 eyes with PTA ≥ 40 percent and an average of two years follow-up after LASIK, but did not identify it as a risk factor for post-LASIK ectasia. Though a good paper in some regards, some serious issues should be highlighted. One huge flaw is that the outcome of ectasia was not present in any of the participants. The outcome is needed to investigate any risk factor – it's like I am investigating mortality and nobody died! It is methodologically wrong

to draw a conclusion about a risk factor from a population that didn't develop the adverse event. Remember, people who have high a PTA might not develop ectasia – it is a risk factor not a predictor. The most important risk factor, for death is high blood pressure (9). If you've got high blood pressure, don't worry, it doesn't mean you will die; it just means that your chance of dying is a little bit higher compared with someone in the normal blood pressure range.

Another flaw was the actual design of the study; cohort studies are for common outcomes with a rare risk factor. Ectasia is not a common outcome – the authors themselves cited it as having an incidence of 0.04–0.6 percent (8). With such a low incidence, a huge number of participants would be needed to draw any conclusions – yet they only had 126. Calculating the sample size that would be needed for this kind of study, based on an incidence of 0.6, you'd need around 3,500 participants with the risk factor. Based on an incidence of 0.04, approximately 53,000 participants would be needed. Using the incidence of 1/2,500 (0.0004 percent) as cited by Randleman et al. (10), over 5 million participants would be needed – that's why cohort studies aren't used to investigate risk factors. Case control studies, like ours (3), should be used for rare outcomes with common risk factors. Furthermore, the patients in

the Saad et al. study were only followed up for an average of two years, but it has been shown that only 20 percent of ectasia cases are detected two years after surgery; this jumps to 50 percent at four years and 75 percent at seven years (11).

We've not finished our work on PTA as a risk factor for ectasia – we'll shortly be publishing our tenth paper. We understand that flap thickness is different to ablation depth so we are working on an equation that gives constants for those variables. There will be people with a PTA higher than 40 percent who will never develop ectasia, because ectasia is a rare adverse event. But our take home message is very simple: high PTA is a risk factor for ectasia. And we've proved it through a correctly-designed case-control study that demonstrated a high odds ratio (3).

References

1. MR Santhiago et al., "Changes in custom biomechanical variables after femtosecond laser in situ keratomileusis and photorefractive keratectomy for myopia", *J Cataract Refract Surgery*, 40, 918–928 (2014). PMID: 24726160.
2. MR Santhiago et al., "Association between the percent tissue altered and post-laser in situ keratomileusis ectasia in eyes with normal preoperative topography", *Am J Ophthalmol*, 158, 87–95 (2014). PMID: 24727263.
3. MR Santhiago et al., "Role of percent tissue altered on ectasia after LASIK in eyes with suspicious topography", *J Refract Surg*, 31, 258–265 (2015). PMID: 25884581.
4. MR Santhiago et al., "Relative contribution of flap thickness and ablation depth to the percentage of tissue altered in ectasia after laser in situ keratomileusis", *J Cataract Refract Surg*, 41, 2493–2500 (2015). PMID: 26452462.
5. MR Santhiago, "Percent tissue altered and corneal ectasia", *Curr Opin Ophthalmol*, 27, 311–315 (2016). PMID: 27096376.
6. MR Santhiago et al., "Ectasia risk factors in refractive surgery", *Clin Ophthalmol*, 10, 713–720 (2016). PMID: 27143849.
7. I Schmack et al., "Cohesive tensile strength of human LASIK wounds with histologic, ultrastructural, and clinical correlations", *J Refract Surg*, 21, 433–445 (2005). PMID: 16209440.
8. A Saad et al., "Evaluation of the percentage tissue altered as a risk factor for developing post-laser in situ keratomileusis ectasia", *J Cataract Refract Surg*, 43, 946–951 (2017). PMID: 28823442.
9. World Health Organization. "Global health risks. Mortality and burden of disease attributable to selected major risks". Available at: <http://bit.ly/WHO risks>. Accessed January 12, 2017.
10. JB Randleman et al., "Risk factors and prognosis for corneal ectasia after LASIK", *Ophthalmology*, 110, 267–275 (2003). PMID: 12578766.
11. M Mirafteb et al., "A modified risk assessment scoring system for post laser in situ keratomileusis ectasia in topographically normal patients", *J Ophthalmic Vis Res*, 9, 434–438 (2014). PMID: 25709767.

PTA Is Not the Way

We need to rethink the concept of PTA as a predictor of post-LASIK iatrogenic ectasia risk

By Alain Saad, Damien Gatinel's
Department, Rothschild Foundation,

Paris, France, Assistant Professor, American University of Beirut, Lebanon.



Percent tissue altered (PTA) has been presented as a significant predictor of post-

LASIK ectasia risk (1,2). But I don't believe that it is – and I'd like to explain why.

There are two major drawbacks that limit the applicability of PTA in our daily practice. Firstly, the way PTA has been computed does not reflect the true biomechanical instability induced by LASIK. Secondly, a risk factor should not be used as a screening metric.

1) The core limitation of PTA:
In their 2014 preliminary paper, Santhiago

et al. (1) achieved 97 percent sensitivity and 89 percent specificity for PTA ≥ 40 as a predictor for ectasia in post-LASIK patients who had normal pre-operative topography. But there was no external validation of these findings until recently. We have made it our objective to evaluate the PTA metric in independent patient populations. We first performed a retrospective analysis of 593 eyes with normal pre-operative topography that underwent LASIK surgery and had a minimum of two years follow up (3). Not a single case of iatrogenic ectasia was found – despite 126 eyes (21 percent) having a PTA ≥ 40 , and with 19 eyes (3.2 percent) having a PTA > 47 – a value which Santhiago et al. (1) reported as having 100 percent specificity. Thus, our independent study did not confirm the specificity of PTA as a predictor for ectasia. In fact, the 126 cases would have been unnecessarily rejected for LASIK surgery if PTA > 40 was applied as a screening tool in this population. A recent study by Djodeyre et al found similar results with 20 percent of their cases having a PTA > 40 and none developing iatrogenic ectasia (4).

We then sought to determine if PTA > 40 was able to detect cases that developed iatrogenic ectasia. For that purpose, we performed a multi-center study (involving Fondation Ophtalmologique Rothschild, Centre D'Ophtalmologie, and Clinique Lamartine, Paris, France; Singapore National Eye Centre and Eye Surgeons at Novena, Singapore; Gavin Herbert Eye Institute, Irvine, California, and Pepose Vision Institute, Chesterfield, USA; Departement d'Ophtalmologie, Université de Montreal, Canada; Narayana Nethralaya Hospital, Bangalore, India; Asian Eye Institute, Manila, Philippines; and London Vision Clinic, London, UK; data under review). Together, we identified 23 eyes with normal pre-operative topography that developed iatrogenic ectasia after LASIK surgery, and compared their PTA with 80 unaffected eyes. PTA > 40 was present in only 11 of the 23 cases (sensitivity = 47.8

percent) and 12 iatrogenic ectasia cases had a PTA < 40 . Groden et al. (5) also recently reported a very low sensitivity of PTA for predicting iatrogenic ectasia (15 percent).

Our patient populations have not been able to validate the utility of PTA. In fact, our studies have shown that PTA is not a reliable analyzer of the true biomechanical instability induced by LASIK surgery. One possible explanation is that when calculating PTA, the cornea is being considered in only two dimensions. PTA assumes that all flaps will have the same diameter and optical zone. When a flap is created with the same planned thickness but a larger diameter, a higher amount of biomechanical instability may be induced, but the PTA value remains the same. In addition, when you go from a 5 mm to a 7 mm optical zone, the volume ablated increases by three-and-half times even though ablation depth only increases by 1.5. All this is not taken into account in the PTA calculation, limiting its benefits.

In addition, the study performed by Santhiago et al. was based only on Placido disc topography, despite the fact that there are clearly reported advantages of using both topography and tomography to detect very early stage of keratoconus (KC) (6–8). Thus, it's difficult to ascertain if some of the patients classified as “normal” based on Placido topography in the PTA study are not in fact “subclinical KC” if tomography was used to classify them. The subclinical KC status would explain why a threshold lower than 40 would be required for PTA to correctly predict ectasia risk in such cases.

2) A risk factor should not be used as a screening tool.

PTA > 40 as a risk factor for ectasia was conceived from data derived from a single population. Confirmation of the validity of PTA has not been achieved in external groups, yet it has been commonly advocated to use PTA > 40 as a screening tool for refractive surgery candidates and to exclude patients with PTA > 40 from LASIK. Different studies (9, 10) have shown how

strongly a risk factor needs to be associated with a disease before it is likely to be a useful screening test. Based on those studies and our data, PTA would barely yield a detection rate of 40 percent, limiting its use and benefits as a screening tool.

I applaud the good work done by Marcony Santhiago and his colleagues in trying to identify new risk factors for iatrogenic ectasia and decreasing LASIK complications. However this concept has not been elucidated effectively and pushing it forwards to be used as a screening tool is detrimental as a whole to refractive surgery.

In future, in order to decrease ectasia risk, we should focus on improving the pre-operative screening of patients by involving both tomographic and topographic assessments rather than Placido disc analysis alone (as done in the PTA study) to identify eyes with early KC. In addition, exploring the concept of percent of volume altered as a risk factor, which thus evaluates the cornea in three dimensions, would be more logical and relevant.

The PTA preliminary results have not been reproducible nor validated in external groups. PTA is not the whole story – there is certainly more to consider.

Special thanks to Damien Gatinel, Cordelia Chan, and Perry Binder for their help in this work.

References

1. MR Santhiago et al., “Association between the percent tissue altered and post-laser in situ keratomileusis ectasia in eyes with normal preoperative topography”, *Am J Ophthalmol*, 158, 87–95 (2014). PMID: 24727263.
2. MR Santhiago et al., “Role of percent tissue altered on ectasia after LASIK in eyes with suspicious topography”, *J Refract Surg*, 31, 258–265 (2015). PMID: 25884581.
3. A Saad et al., “Evaluation of the percentage tissue altered as a risk factor for developing post-laser in situ keratomileusis ectasia”, *J Cataract Refract Surg*, 43, 946–951 (2017). PMID: 28823442.
4. MR Djodeyre et al., “Long-term evaluation of

- eyes with central corneal thickness $<400\ \mu\text{m}$ following laser in situ keratomileusis", *Clin Ophthalmol*, 10, 535–540 (2016). PMID: 27099459.
5. LR Groden et al. "Percentage tissue altered in a large series of post-femtosecond LASIK ectasia cases". Presentation at the American Society of Cataract and Refractive Surgeons annual meeting; Los Angeles, California; May 5–9, 2017.
 6. IC Ramos et al., "Variability of subjective classifications of corneal topography maps from LASIK candidates", *J Refract Surg*, 29, 770–775 (2013). PMID: 23980708.
 7. R Ambrósio Jr et al., "Novel pachymetric parameters based on corneal tomography for diagnosing keratoconus", *J Refract Surg*, 27, 753–758 (2011). PMID: 21800785.
 8. A Saad and D Gatinel. "Topographic and tomographic properties of forme fruste keratoconus", *Invest Ophthalmol Vis Sci*, 51, 5546–5555 (2010). PMID: 20554609.
 9. C Chan et al., "Validation of an objective scoring system for forme fruste keratoconus detection and post-LASIK ectasia risk assessment in Asian eyes", *Cornea*, 34, 996–1004 (2015). PMID: 26165793.
 10. NJ Wald, AK Hacksshaw, CD Frost. When can a risk factor be used as a worthwhile screening test? *BMJ* 1999;319:1565–8

The Anti-Social Network

E-posters save space and are more easily shared, but they risk stripping away interaction and the potential of collaboration – and the advancement of science and medicine – that traditional posters offer.



By Martine Jager, Professor, Leiden University Medical Centre, The Netherlands.

Five or ten years ago, conferences were bigger. Not in terms of the number of attendees, but they were physically bigger. They were hosted in huge halls (the size rock bands would play), full of people, and some of the halls were devoted to one thing: posters. However, conferences are increasingly turning to e-posters: a bank of computers on a table where delegates can view a presenter's short slide deck, or some small 'pods' – a

small seated area where somebody gives a PowerPoint presentation on a large TV screen, during a short, pre-allocated time slot. Here is another point of view. I ask myself: are these actually "posters"? They seem to me to be more like mini-lectures, and I think we need to consider what is lost from moving from physical posters to e-posters.

While the move to e-posters may save a lot of space, I think we lose something in the process. The biggest potential advantage of online posters is that people should be able to view the poster before or after the congress. But it's regularly the case that delegates can only view e-posters on site, on specified computers, and if posters are available for viewing outside of the congress, often, a paid subscription is required. Just consider the ARVO annual meeting with its traditional poster session approach. People give a poster presentation, others walk by and the discussion begins. ARVO is built around networking opportunities – and, for many people, the poster session is the highlight of their congress. You can understand why: for each and every poster topic, you're guaranteed an area with a high concentration of expert researchers, either presenting or reading the posters on display for a 2–3 hour period. You have access to these bright minds, you are able to ask questions, have conversations, and get to know these

people. I've known the humble poster session be the source of long-lasting collaborations – even friendships. Such meaningful interactions cannot easily be copied electronically, if at all, when the only way you can ask questions is via e-mail, or in the short period after a mini-presentation before the presenter moves off to their next commitment at the congress.

All of this is most important to the education of young clinicians and researchers. They are the ones that need the opportunity to discuss their work and direction with other people the most – people who are likely to be much more experienced and knowledgeable, with a different point of view and something real to contribute. Such interaction moves science and medicine forward! My concern is that where only an electronic poster exists, the presenter is less able to broaden their network, and the viewer is unable to gauge the talent or enthusiasm of the presenter. There's no networking and no opportunity for debate. Collaborations aren't made and ideas aren't generated. So while e-posters have the advantage of taking less space and might be able to be disseminated outside of the conference, they're not a like-for-like replacement for the traditional poster session. As conference organizers move increasingly towards e-posters, I'd ask them to consider pausing and considering what they're losing in the process.



PERFECTION ACHIEVED

(BUT NOBODY SEEMS TO CARE)



By Lawrence Hirst

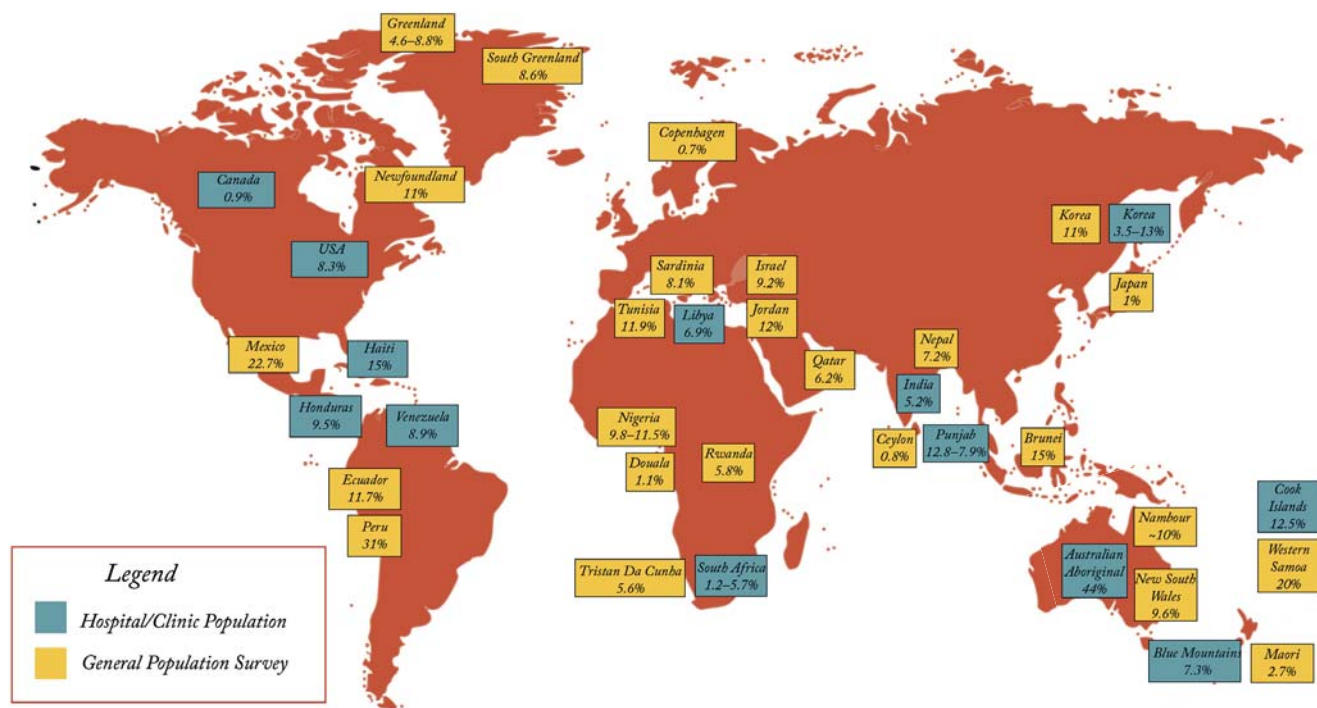

Northern Australia is rife with pterygium, the conjunctival disorder that's seen primarily in tropical and some subtropical regions of the world (Box 1). It's characterized by a non-malignant, slow-growing proliferation of fibrovascular tissue over the cornea, and the disease processes involve a fibrovascular reaction, chronic inflammatory cell infiltration, angiogenesis, and fibroblastic proliferation and invasion (1). But if you needed to choose a single word to describe it, you probably wouldn't choose 'pretty' (Figure 1). In Brisbane, Queensland, where I was born, raised (and went to medical school), almost every ophthalmologist removes them as a routine part of their practice. They consider it to be a trivial disease and want to perform the simplest surgery to get rid of it. During my undergraduate days back in the late 1960s, most people just scraped it off in the office and sent the patient off for radiotherapy to prevent recurrence.

I left Brisbane in 1973 and travelled 1,000 miles south to work in Melbourne, which was followed by stints in the US: Baltimore

in 1976, then St Louis, Missouri in 1983. I saw hardly any cases during my travels away from home. But in 1986, I returned to the Princess Alexander Hospital in Brisbane and was faced, once again, with many cases of terrible pterygium.

Pterygium might often be thought of as being a trivial condition – and frequently, it is. But occasionally, it's blinding. At the time, what struck me most was that the methods being used to treat pterygium could actually lead to patients losing their vision – or even their eyes. The biggest villain was radiotherapy: it can cause scleral necrosis, leading to scleral thinning, which leaves patients' eyes more vulnerable to infection. We all know the potential consequences of endophthalmitis.

One problem with a "trivial" disease is that it does not receive much attention. Beyond one or two small studies, there was no real data on the true incidence of pterygium in the country – and certainly very little scientific research into how to treat it. It was just word of mouth: "Gee, that seems to work, so we'll do it too."



Data from LW Hirst, "Chapter 2. Distribution, risk factors, and epidemiology of pterygium", in *Pterygium*, ed. HR Taylor, Kugler Publications (2000). ISBN-10: 9062991742.

Box 1. Global incidence of pterygium.

THE APPLICATION OF SCIENCE

The first thing I did after seeing such terrible cases on my return to Australia was to try and put some science into the subject: epidemiology and statistics. To build our framework, we needed to understand two aspects of pterygium: how often it occurred, and the success and complication rates of existing treatments.

The first part was dealt with through collaboration – someone was organizing a dermatology population study in a city not far from Brisbane (2), so I got involved. It turned out that the pterygium prevalence rate in this city was 10 percent of the population aged over 18 years – making it an extremely common condition – and it was likely to be similar across Queensland. The second task was to examine the success rates of existing treatments. The recurrence rates at the Princess Alexandra Hospital were 42 percent (3)! And that made it clear to me that we not only had a very common disease, but it was also being poorly treated.

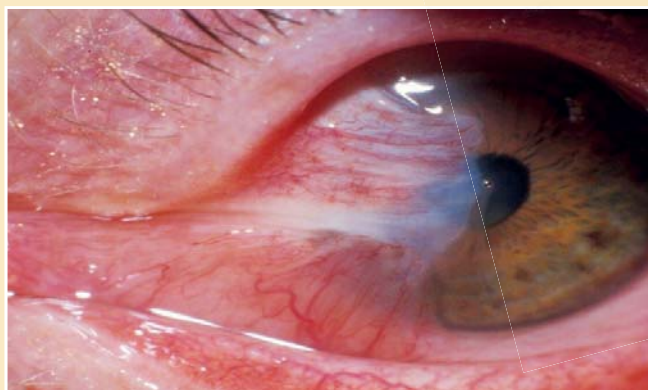


Figure 1. An external photograph of a pterygium

Later, we found out that you need to follow patients for at least a year – doing so identifies 97 percent of all recurrences (4).

We then tried to identify over a thousand consecutive patients who had been treated with radiotherapy (around 25–30 percent of patients with pterygium received radiotherapy at the time). We were looking for patients 10 years after radiotherapy – but,



of course, it's very difficult to follow patients a decade after a treatment. Nevertheless, we did find 500 of the 1,000 – 13 percent of whom developed scleral necrosis; and two lost their eyes because of endophthalmitis thanks to a thinned sclera (5). I'm

moderately proud of my achievement: it helped me manage to knock radiotherapy on the head for pterygium in Queensland, so it's very rarely used now. And though I may be overly filled with hubris, I'll take the credit for that!

IMPROVING THE INTERVENTION

Conjunctival autografting – the removal of pterygium and placing a small piece of conjunctiva from elsewhere is an old technique, but it was brought to prominence in 1985 by an article from a former mentor of mine in the US (6). It's turned out to be the gold standard for the treatment of pterygium. But, in the meantime, many of the people who previously used the quick, simple and dirty method of scraping and referring the patient for radiotherapy, started using the equally (in my opinion) quick and dirty method of scraping and using mitomycin drops instead. I decided to investigate whether there was a better method. I hit many dead ends;

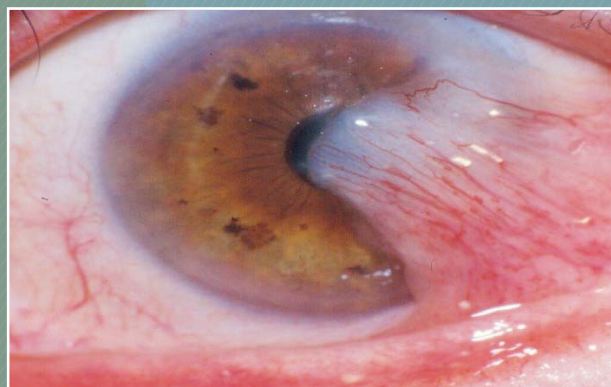
I tried other chemo drops and tried various other approaches, and finally decided that conjunctival grafting was the way to go. But I was still seeing recurrence rates of between 5 and 15 percent, which I thought was unsatisfactory. Additionally,

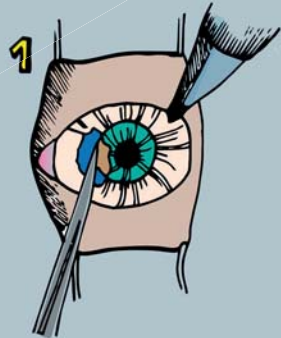
I soon realized that patients wanted good cosmetic results as well. Most of the small grafts being prepared did not result in good cosmesis, with visible (and rather ugly) scars all the way around the graft.

Joaquim Barraquer had hypothesized 30 years beforehand that the reason pterygia came back was because of the activation of Tenon's layer – and that the removal of Tenon's layer would reduce the recurrence rate after pterygium removal. I decided that he was probably correct, so I started removing more and more Tenon's around the medial rectus muscle. As soon as I started doing that, the defect in conjunctiva grew and grew, because it turns out that the Tenon's drags the conjunctiva onto the cornea. If you just section the pterygium at the limbus, you already get a sizable defect in the conjunctiva over the sclera. But if you then perform an extensive removal of Tenon's as well, you get a quite huge defect in the conjunctiva – which goes back to the position where it had come from. As I was making increasingly large conjunctival defects, I ended up putting in larger and larger grafts. And that was the start *P.E.R.F.E.C.T.* for PTERYGIUM® (pterygium extended removal followed by extended conjunctival transplantation; Box 2 (7)).

PTERYGIUM KEY FACTS

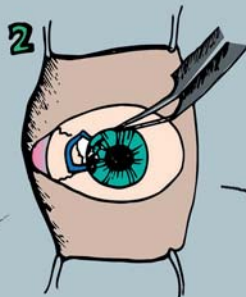
- Derived from the Greek Word “Pterygos”, meaning “small wing”
- It manifests as a wing-shaped fleshy band of fibrovascular tissue growth over the cornea
- It may disturb vision
- The closer you get to the equator, the greater its prevalence
- Men are twice as likely to develop it as women
- We believe that wearing sunglasses should help to prevent it





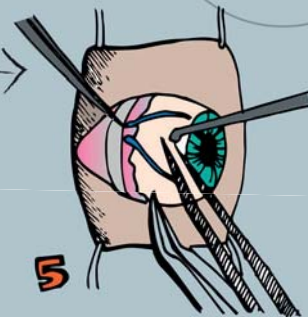
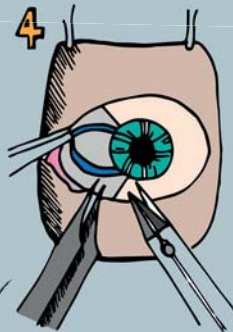
Heavy marking and incision of pterygium at limbus.

Stripping of pterygium from the corneal surface. The conjunctival edge retracts as a result of incising the Tenon's layer at the limbus and the removal of the traction from the pterygial head.

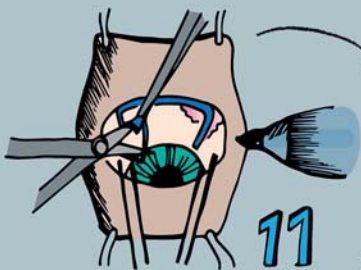


Separation of superior conjunctiva from underlying Tenon's layer.

Separation of superior Tenon's layer from underlying sclera.

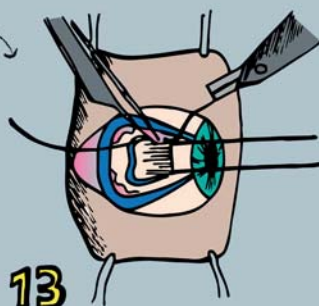
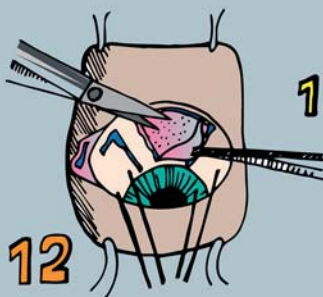


Tenon's layer prolapse after initial limbal Tenon's incision with increasing Tenon's excision anteriorly-to-posteriorly of ~10 to 15 mm width.



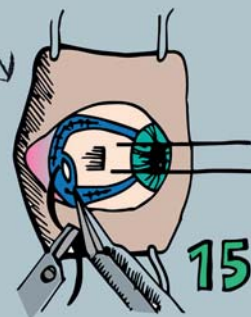
Marked donor conjunctiva leaving a 3-to 5-mm bridge of conjunctiva between the donor site and recipient site. The conjunctiva is undermined with scissors.

Reflected donor conjunctiva leaving 2 mm of limbal conjunctiva intact.



Suturing of the limbal corner of the graft to the sclera and the free edge of the conjunctiva 2 mm back from the limbus.

Suturing of the posterior corner of the graft to the sclera approximately 15 mm from the limbus. Note the tension in the paralimbal edge of the graft.



The final average size of the conjunctival defect and pterygium.

Box 2. The P.E.R.F.E.C.T. for PTERYGIUM®

P.E.R.F.E.C.T. for PTERYGIUM® is a registered trademark to The Australian Pterygium Centre.

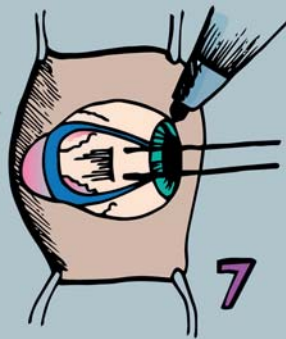
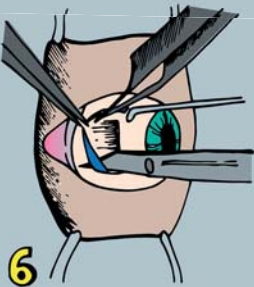
"This procedure takes an hour to perform, thanks to the fact that it is meticulous surgery with a focus on dissection planes."

IT'S GOT TO BE PERFECT

When I started performing this procedure, the recurrence rate dropped remarkably (8). But I still wasn't entirely happy with the cosmetic appearance. It was pretty good – if you have bare sclera and put conjunctiva down and suture it to bare, Tenon's-free sclera (and to any edges of existing conjunctiva) the resulting scar is almost invisible. So when I suture a graft in, you won't be able to identify where it has been sutured to the existing conjunctiva after a few months – except for the region where the conjunctiva was sutured to the other free edges of conjunctiva that aren't

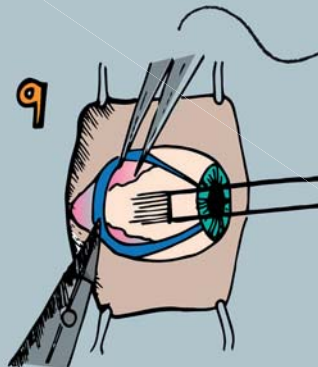
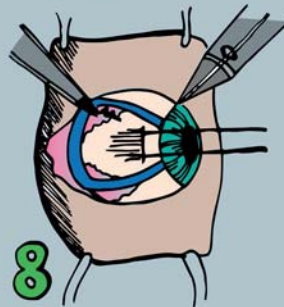


Paracaruncular Tenon's layer removal almost to the caruncle. Now that the Tenon's layer has been removed extensively, note the expanded size of conjunctival defect as a result of retraction of conjunctival edge.



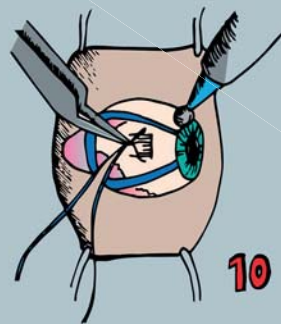
Heavy marking of the conjunctival edge. Note the size of the conjunctival defect and extensive retraction of cut edge of residual Tenon's layer.

Minimal trimming of the superior edge of the conjunctiva.

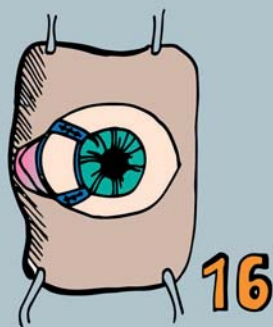


Total excision of the semilunar fold resulting in 1 to 3 mm of residual paracaruncular conjunctiva.

Diamond burr smoothing of the corneal surface. Note the final size of the conjunctival defect after removal of semilunar fold and trimming of edges.



The final result with eye in primary position and the new semilunar fold.



17A



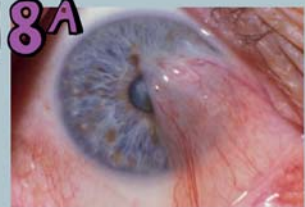A. Cross-section through one posterior corner suture showing the fixation of this point of the graft to the sclera while the eye is pulled temporally.

B. Cross-section as above, but with the eye in the primary position showing the creation of the new semilunar fold by virtue of the scleral fixation of the superior and inferior posterior corners of the graft and the subsequent tucking of the continuous paracaruncular suture line under the fringe of residual paracaruncular conjunctiva.

17B

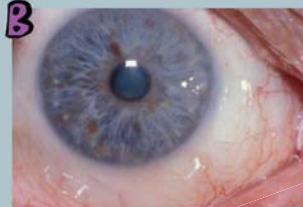


18A



Conjunctiva and cornea (A) before pterygium removal and (B) 1 year after removal. Note the absence of any visible suture line or vascularization, the reconstructed semilunar fold, and the normal-appearing limbus.

B



tacked down to the sclera. I've always found the nasal edge of the scar near the caruncle to be a problem – so the next step was to excise the semilunar fold and create a new semilunar fold that was able to hide the scar that always occurs when you suture conjunctiva to conjunctiva (7). I also realized, adding further finesse to the procedure, that if you took a very thin graft from the top part of the eye – so good, so thin, with virtually no adherent Tenon's, that there was no bleeding from the underlying Tenon's – it epithelialized very quickly, and within a few months you couldn't tell that the graft had been taken. In fact, within six to 12 months, you can harvest a second graft from the same site.

PERFECTION PROVES PROBLEMATIC

However, *P.E.R.F.E.C.T.* for PTERTYGIUM® isn't perfect. Despite the superb cosmesis and fantastically low recurrence rates, it has a major problem. It's not an easy procedure to perform, and because it's difficult, it can take a long time. Most people who just scrape the pterygium can do it in five minutes in their office. Even those that go into the operating room and perform a graft take at most 20 to 30 minutes to perform it. Routinely, this procedure takes an hour to perform, thanks to the fact that it is meticulous surgery with a focus on dissection



BUILDING A PTERYGIUM PRACTICE

It was a very telling finding. The thinner the graft and the more immaculate you leave the Tenon's from the graft retrieval area, the better the graft is and the more quickly it integrates when it's transferred over into the pterygium site. And that, in short, is the essence of *P.E.R.F.E.C.T.* for PTERYGIUM®.

For many years, I was a corneal surgeon, and had the largest corneal transplant practice in Australia. But about 10 years ago, the methods of transplantation changed fairly dramatically. To be frank, I did not wish to go through the learning curve that was required for these new methods (or to have my patients go through that learning curve either). At the same time, my pterygium practice was building up. I handed off my practice to someone else and took the risky step of only doing pterygium surgery.

I was still doing this as CEO of the Queensland Eye Institute. But I wanted an identifiable place for this pterygium practice, so for the first time in my career, I went into private practice.

It's true that a practice lives or dies by referrals. It's amazing how much word of mouth has built the pterygium surgery practice. Probably one in five of my patients are friends or relatives of people who have had the procedure done, and the rest are referrals from optometrists and general practitioners.

I do maybe 300 pterygium surgeries a year – a third to a half of all pterygium surgeries in Queensland – and yet I probably get fewer than about 10 patients referred by other ophthalmologists, who continue to do their own. This is also fairly telling for a condition that they don't particularly care to treat, and which they treat trivially: they're not prepared to pass them on to someone who's made it their life's practice.

"I followed a thousand consecutive patients – 99 percent for more than a year – and found just one recurrence."

planes. The other factors to consider are that you need an assistant – and that's an added expense that nobody else has – and you need to give the patient peribulbular anesthesia (other methods just see surgeons injecting a bit of anesthetic underneath the pterygium).

However, the advantages continue to stack up; for example, when done properly, patients experience less pain after surgery. In my fashion of wishing to investigate further, I followed a thousand consecutive patients – 99 percent for more than a year – and found just one recurrence (8) – that's two orders of magnitude better than most other recurrence rates. I've also performed cosmetic studies to look at whether it's possible for people to identify that a pterygium was removed from the eye. It turned out that it wasn't possible – the cosmetic result was so good. I'm currently trying to follow people who received my *P.E.R.F.E.C.T.* for PTERYGIUM® surgery more than a decade ago, to make sure that my 10 year results follow my one year results.

WHO CARES?

Now, I really do not want to keep this method of pterygium removal as a personal procedure. I would like to train others, but it's a difficult technique that requires a mini-fellowship with me. I have been almost universally unsuccessful in this regard. I've managed to train one other surgeon in Brisbane and one



PTERYGIUM HISTOPATHOLOGY

Pterygium is characterized by these basic elements:

- Epithelial covering of atrophic conjunctiva
- Degenerated, thickened, hypertrophied connective tissue that contains abnormal collagen
- Neovascularization, with vessels dispersed among the collagen fibers
- Hyperemic episcleral bed beneath the pterygium
- Tenon's capsule is incorporated into the body – and contributes to its vasculature and bulk

in Townsville, who can do it as well as me. But that's it. My synopsis? It's very sad and discouraging. We now have a gold-standard method with more scientific proof of any other method, and yet doctors are not prepared to embrace it on behalf of their patients and themselves. One upshot is that I'm getting increasing numbers of patients to my pterygium-only practice...

Every year, I go to the largest meeting in the US – the American Academy of Ophthalmology – and for about 11 years, I've been trying to teach my method. The

problem is, you can't learn this method from a lecture or a workshop; you can only learn it by actually sitting down with the person who developed it. And therein lies another issue: obtaining professional registration for foreign doctors so they can actually do surgery with me in Australia is a heinous procedure – it's more difficult than the surgery!



“We now have a gold-standard method with more scientific proof of any other method, and yet doctors are not prepared to embrace it on behalf of their patients and themselves.”

And so I'm trying to do the reverse. A Canadian ophthalmologist who came to Australia for a week to watch me perform this procedure was so impressed that he wanted to learn it. After 12 months of correspondence and thousands of dollars, I spent three days in Saskatoon assisting this ophthalmologist in the learning phase. It's more interest than I've received from Australian ophthalmologists who could come and work with me without any of these issues and difficulties.

Consider this article an open invite. If you treat patients with pterygium, and you want to do the best for them – in terms of both cosmesis and avoiding recurrence, you should set your sights on *P.E.R.F.E.C.T.* for PTERYGIUM®. If you're interested enough to learn, I'm more than happy to show you how.

Lawrence Hirst is a pioneer of multiple ocular surgical techniques, including corneoscleral grafts and novel approaches for using tissue adhesive in perforated eyes. He developed the P.E.R.F.E.C.T. for PTERYGIUM® surgical technique and now performs pterygium surgery exclusively at the Australian Pterygium Centre, in Graceville, Queensland, Australia and in North Sydney as well. He can be contacted at lawrie@tapc.net.au.

References

1. JC Hill, R Maske, "Pathogenesis of Pterygium", *Eye*, 3, 218–226 (1989). PMID: 2695353.
2. J Chui et al., "Ophthalmic Pterygium. A Stem Cell Disorder with Premalignant Features", *Am J Pathol*, 178, 817–827 (2011). PMID: 21281814.
3. JS Ambler, LW Hirst, CV Clarke, AC Green, "The Nambour Study of Ocular Disease 1. Design, study population and methodology", *Ophthalmic Epidemiology*, 2, 137–144 (1995). PMID: 8963917.
4. A Sebban, LW Hirst, Pterygium recurrence rate at the Princess Alexandra Hospital. *Aust N Z J Ophthalmol*, 19, 203–206 (1993). PMID: 1958364.
5. LW Hirst, A Sebban, D Chant, "Pterygium recurrence time", *Ophthalmology*, 101, 755–758 (1994). PMID: 8152771.
6. KR Kenyon et al, "Conjunctival autograft transplantation for advanced and recurrent pterygium", *Ophthalmology*, 92, 1461–1470 (1991). PMID: 4080320.
7. RA Weise et al., "Conjunctival transplantation. Autologous and homologous grafts", *Arch Ophthalmol*, 103, 1736–1740 (1985). PMID: 3904687.
8. LW Hirst, "Prospective study of primary pterygium surgery using pterygium extended removal followed by extended conjunctival transplantation", *Ophthalmology*, 115, 1663–1672 (2008). PMID: 1855531.
9. LW Hirst, "Recurrence and complications after 1,000 surgeries using pterygium extended removal followed by extended conjunctival transplant", *Ophthalmology*, 119, 2205–2210 (2012). PMID: 22892149.

BUILT FOR THE
NEXT GENERATION.

BUT READY FOR THIS ONE.



Experience Stellaris Elite™—where real-time
responsiveness enables exceptional stability.

Stellaris Elite™
Vision Enhancement System

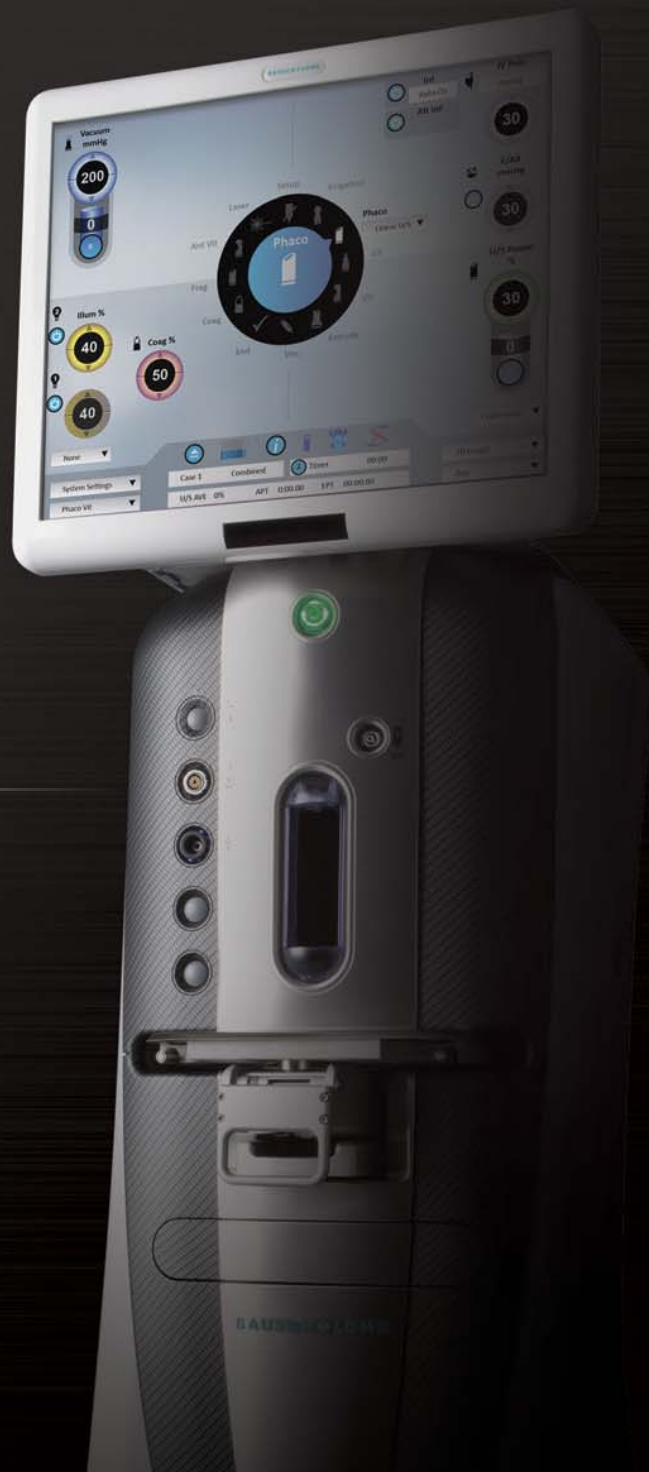#TestDriveBausch

(800) 338-2020 | StellarisElite.com

Indications: The Bausch + Lomb Stellaris Elite™ vision enhancement system is intended for the emulsification and removal of cataracts, anterior and posterior segment vitrectomy. The system is designed for use in both anterior and posterior segment surgeries. It provides capabilities for phacoemulsification, coaxial and bimanual irrigation/aspiration, bipolar coagulation, vitrectomy, viscous fluid injection/removal and air/fluid exchange operations. The Stellaris Elite vision enhancement system configured with the laser module is additionally intended for retinal photocoagulation and laser trabeculoplasty. **Contraindications:** All Systems: Use of accessories not designated by Bausch + Lomb for use with this equipment may result in serious permanent patient injury, adverse surgical outcome, or damage to the equipment. Systems with Laser Module: Photocoagulation is not indicated for patients without pigmentation (albino eyes). In addition, Laser Indirect Ophthalmoscope (LIO) is not indicated for cases involving laser photocoagulation within the arcades. **Warnings:** All Systems: Implantable defibrillators present a risk of injury if triggered by a fibrillatory event during intraocular surgery. Electromagnetic interaction between the phacoemulsification (phaco) handpiece and an implanted cardiac pacemaker is unlikely, but cannot be ruled out. Systems with Laser Module: All support personnel who are present during laser treatment must wear appropriate laser protective eyewear. **DO NOT** look directly into the aiming or treatment laser beam. Use of unapproved delivery devices may cause inaccurate laser delivery which could result in serious permanent patient injury. **This is not all you need to know. Systems with Laser Module: Misuse of the laser system may lead to dangerous situations and severe injuries. All Systems: See the appropriate Operator Manual for detailed directions, proper use, and full risk and safety information. CAUTION:** Federal (U.S.) Law restricts this device to sale, by or on the order of a physician.

®/™ are trademarks of Bausch + Lomb Incorporated or its affiliates.

©2017 Bausch + Lomb Incorporated. STL.0021.USA.17



LONG TERM VISION | FOR YOUR PATIENTS | FOR YOUR PRACTICE

BAUSCH + LOMB



In Practice

Surgical Procedures

Diagnosis

New Drugs



28–32

A Small Solution to a Significant Problem

M. Scott Hickman on small incision cataract surgery (SICS) – the cataract procedure of choice in international ophthalmology (and a handy procedure to have in in your surgical armamentarium to deal with hard cataracts).

33–35

Scleral Buckling 101

PPV might be a popular procedure for fixing RRDs, but Alex Ringeisen and colleagues say that there is still a place for primary scleral buckling, and so review the hows and whys.

A Small Solution to a Significant Problem

Beginning small incision cataract surgery (SICS) at home and abroad

By M. Scott Hickman

It is Friday afternoon at 4:59 pm, and the patient shown in Figure 1 walks through your door.

You are most likely to:

- Refer!
- Chop and phaco, with my favorite retina doctor operating that day in the next room
- Extracapsular cataract extraction (ECCE), with an incision at the limbus and 15 interrupted sutures
- Small incision cataract surgery (SICS)

At a Glance

- SICS is a sutureless cataract surgery that has multiple advantages over traditional phacoemulsification and ECCE procedures*
- Not only is SICS the procedure of choice for international ophthalmology, it is useful when dealing with ‘catarocks’ – dense and mature cataracts*
- Here, I explain the benefits of SICS and provide a step-by-step guide to performing the procedure*
- Useful resources and training courses are highlighted to help any surgeon who wants to learn SICS.*



Every cataract surgeon has come across the ‘catarock’, the super hard lens that requires prolonged phacoemulsification time and increased energy delivery to deal with – and the subsequent post-operative corneal edema. This can lead to extended healing times and occasionally further corneal surgery, such as Descemet’s membrane endothelial keratoplasty (DMEK) or corneal transplantation. To deal with this, most of us have learned to use a chopping technique with phacoemulsification, or to perform traditional ECCE with a large limbal incision – but this requires sutures and can induce large amounts of astigmatism.

However, surgeons in many parts of the world perform “sutureless” SICS developed by Blumenthal and Ruit in the 1990s (1,2). Its advantages over traditional ECCE and phacoemulsification include reduced cost, operating time, and post-operative

corneal edema, a self-sealing scleral incision, and the need for less technology and equipment. In a comparative study, both SICS and phacoemulsification were shown to achieve excellent visual outcomes (3).

SICS is an excellent procedure to perform, whether it is a planned surgery or a conversion procedure in cases where the lens is too dense to safely perform phacoemulsification, or when the capsule is broken and the lens needs to be removed in one piece. It is also typically the surgery of choice if one wants to work in international ophthalmology.

There are many paths open to the phaco surgeon who wants to learn SICS. Surgeons will often start out with articles and surgical videos that are easily found online, and then move on to a wet lab SICS course. After completing the wet lab, some will begin operating on patients, others will take a mentored

course with an expert teacher who guides them through their first 20 or 40 cases via a teaching microscope or video screen and jump in when needed to ensure good outcomes.

After the first 20 to 40 cases, the surgeon will often operate independently, but with a more experienced doctor working next to them on another microscope in the same room and available as needed. This is especially true in international ophthalmology, where the microscopes and operating room can be more challenging, in addition to the more advanced pathology often seen. It can take around 300 to 500 cases to become a fully confident SICS surgeon, but it's a process worth doing. There are many references to begin learning about SICS (see Sidebar: "Resources to get you Started").

Step-by Step SICS

Surgeon position, bridle suture, conjunctival cutdown

The patient is typically given a peribulbar block, prepped with an iodine-based antiseptic, and a lid speculum placed as with typical phacoemulsification. The characteristics of an "ideal first patient" are given in the Sidebar on the next page.

Most beginning surgeons sit superiorly. The advantages to this are the potential placement of a bridle suture under the superior rectus for better exposure, and coverage of the wound by the lid (Figure 2). Another option is a temporal approach that allows easier exposure and leads to less astigmatism, but less coverage of the wound. A compromise is sitting superior-temporally, which gives good coverage of the wound, but potentially less surgeon-induced astigmatism (4).

The next step is the conjunctival cutdown made for approximately 6–8 clock hours down to bare sclera. Scleral bleeding can be controlled by cautery; many prefer wet field cautery, if available.

Resources to get you Started

Free online references for SICS

- This website from Global Sight Alliance features videos on working in international ophthalmology and detailed lectures on the SICS technique. <http://classroom.globalsight.org/>
- In this video, Will Dean provides a nice overview of the technique. <http://bit.ly/Will-Dean>

Books and articles to purchase

- G Tabin and M Feilmeier. "Cataract Surgery in the developing world", AAO Focal Points 2011 Module, eBook. Available at: <http://bit.ly/Tabin2011>
- BA Henderson. "Manual Small Incision Cataract Surgery", First edition, Springer International Publishing: 2016. Available at: <http://bit.ly/HendersonSICS>

Paid wet labs for SICS

- Wet labs are held at the yearly meetings of the American Academy of Ophthalmology and the American Society of Cataract and Refractive Surgery, and at various times of the year with SEE International.
- This June at the Royal College of Ophthalmologists in London, UK, SEE is sponsoring a SICS wet lab featuring Geoffrey Tabin of the Himalayan Cataract Project, and this would be a great place to get started: <https://www.seeintl.org/msics/london-june-2018/>

Mentored surgery

- This is probably the hardest and most expensive to set up. As most have quite a wait time, it is best to start planning early.
- SEE International (under level 2 training): <https://www.seeintl.org/msics/>
- Vision Outreach International: <http://visionoutreach.org/programs/msics-training>

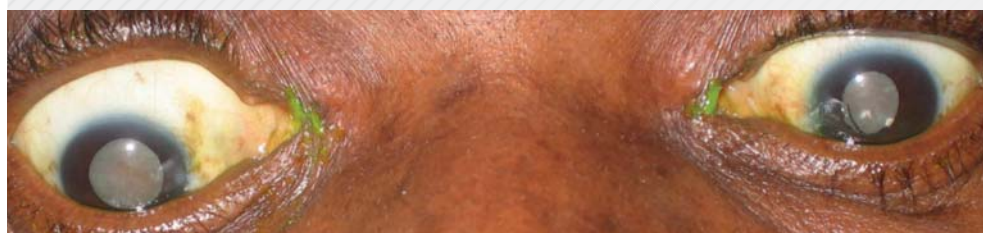

Figure 1. Mature cataracts.

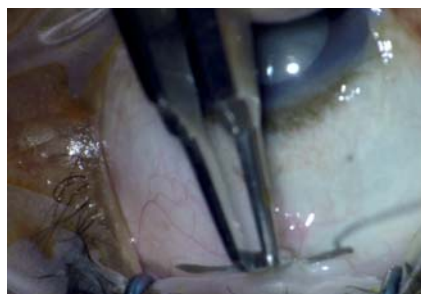

Figure 2. Placement of the bridle suture.

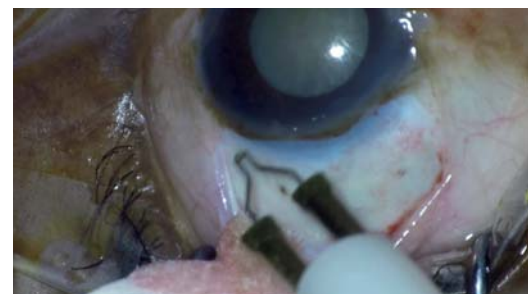

Figure 3. Cautery of scleral vessels.

Characteristics of an ideal first SICS patient

- Be able to communicate with the patient directly or through an interpreter
- Anxiolytic given
- Good block
- Lack of trauma, pseudoexfoliation, white, or super mature cataract
- Lack of deep set eyes or prominent brow
- Red reflex present
- Large pupil
- Vision blue and a quality viscoelastic present
- Sharp blades
- Wet field cautery
- Instruments and IOLs you are familiar with
- Decent microscope with a teaching arm for your scrubbed mentor
- It is good to know the microscope set up before you go on your first few international trips. If you need to source one, try to borrow one from a friendly non-governmental organization (NGO).

Scleral incision

When first learning the procedure, it is best to measure and mark the size of the incision, but be aware this will vary greatly based on the size of the lens (Figure 4, these are the measurements recommended by Tabin and Feilmeier (5)).

The initial scleral incision can be done with a 15 (or similar) blade or the

crescent blade at 50–75 percent scleral depth. Another great option is a 250 μ m depth guarded blade to get you started out at the right depth. It is helpful to get a good grip with .12 forceps and to have a dry scleral bed. If you do a frown incision you will reduce the amount of surgically induced astigmatism described by Bonnie Ann Henderson (6) (Figures 5 and 6), but it can be a little harder to do starting out.

The crescent blade is then used to make a ‘wiggle’ incision that follows the shape of the globe. Continue the incision 1–1.5 mm into clear cornea but be sure to bevel up once clear cornea is reached to compensate for the increased curvature of the cornea. If the crescent blade is a) ‘buried in the incision’ peripherally and b) half the length of crescent blade centrally, it is usually the correct size.

Figures 7 and 8 show tunneling up to clear cornea with the crescent blade. Notice that the blade is barely visible under the sclera, a sign of the correct 50–75 percent scleral depth. Centrally the scleral incision is also about half the length of the crescent blade, a sign it is about the correct length.

Once the scleral incision is completed, a paracentesis (or two) is made (Figure 9), and viscoelastic or methylcellulose injected.

A microkeratome blade is used to enter the anterior chamber. The microkeratome needs to be at the extent of the corneal scleral incision, and then aimed at the center of lens. If you see a dimple or a pucker, you have done it correctly (Figures 10 and 11). Some surgeons will make a single stab, then insert more viscoelastic and perform the capsulotomy. Others will make the full incision at this point. It is best to enter the anterior chamber and fully extend the incision with one cut on each side as it reduces the risk of a Descemet’s detachment – try not to ‘saw through’ if possible with a dull knife.

Capsulotomy

The rest of the surgery is very much like traditional ECCE. You can perform a capsulotomy in many different ways: can-opener, continuous curvilinear capsulotomy (CCC), V-shaped capsulotomy, or linear capsulotomy. Most beginning surgeons will do what their mentor advises, and most seem to start out with a can-opener.

The can-opener capsulotomy is often used because it is easier to perform under suboptimal conditions, such as a poor red reflex, an inadequate operating microscope, or a lack of vision blue stain. When doing a can-opener capsulotomy, it is good to remind oneself that the tear is made perpendicular to the puncture of the needle. To keep the tears extending peripherally, the needle should start distal and move toward the center of lens and connect new punctures to the last one (Figure 12).

Many consider a CCC better if a red reflex is present and if it can be made to a large size (6–8 mm), as it has less tendency to extend peripherally and cortical removal is easier as there are no capsular tags to pull on. If it is too small it can be hard to get the lens out of the bag, or one can get a radial tear trying to force a too large lens through a too small CCC. One option if the CCC is too small is to make relaxing incisions on the anterior capsule.

Another technique to know of especially in the presence of a small pupil is a V-shaped capsulotomy, which is done when two cuts on the capsule are made with the bevel of a 25 or 27-gauge needle in a V pattern. The two cuts meet, and the anterior capsular flap is then lifted up. The flap is then completed after the IOL is inserted. A more advanced technique is a linear capsulotomy.

Lens removal

Prolapsing the lens into the anterior chamber can be performed in various ways and is often hard for a beginning

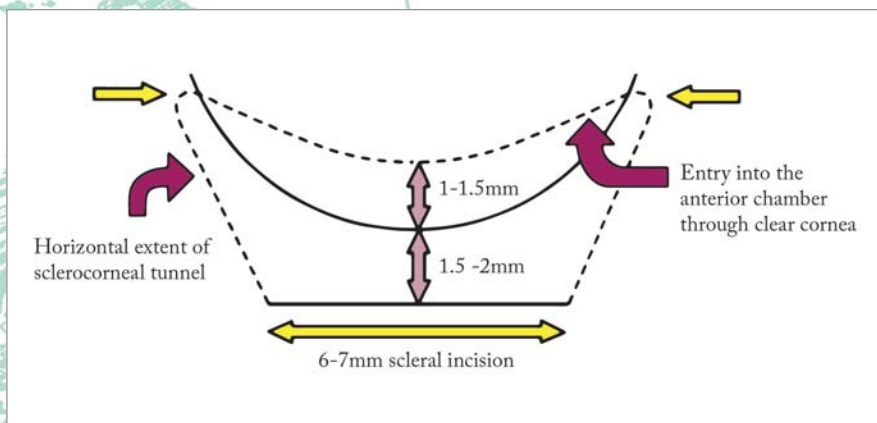


Figure 4. Scleral incision size. The size will vary some based on the size of the lens.



Figure 5. Depth of scleral incision and frown incision.

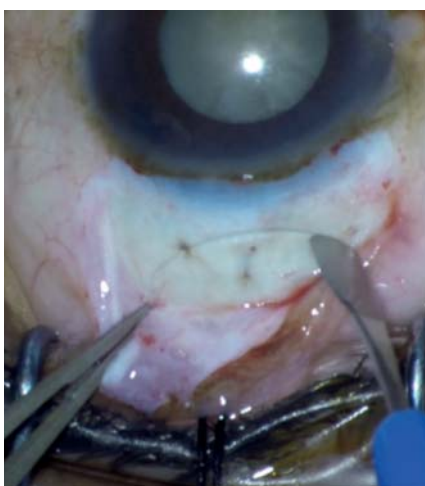


Figure 6. Initial scleral incision in frown shape.

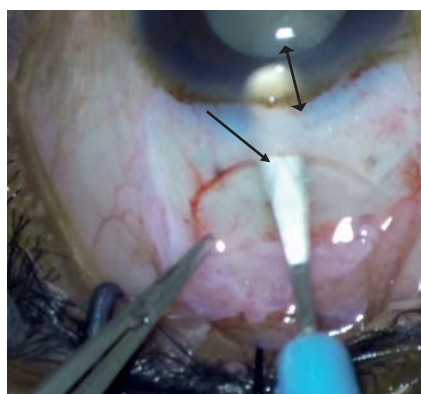


Figure 7. Tunneling up to clear cornea. Note the blade is just visible under the sclera, a sign of being at the correct depth. Incision length should be about half of the crescent.

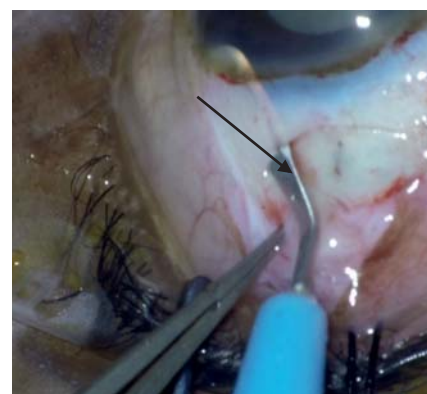


Figure 8. Scleral tunnel, with "burying" of the crescent blade. Crescent blade is "fully buried" at the peripheral extent of the scleral incision, a sign of correct length.

SICS surgeon. One way is fluidic, via hydrodissection or viscodissection. Another is mechanical by dialing the lens completely out of the bag with a Sinskey hook. Once the lens is in the anterior chamber it is important to insert viscoelastic between the lens and the cornea and under the lens to push back the bag and iris to isolate the lens.

Lens removal (Figure 13) through the scleral incision needs to be performed gently. Avoid forcing the lens through the incision as the capsule can be broken; you can always make the incision bigger and put in a stitch. The eye is typically pulled down with .12 forceps and most beginning surgeons use a lens loupe or irrigating vectis to remove the lens. It is also important to visualize the distal end of the lens loupe so that the distal end

does not pull on the iris as well. Other techniques include using viscoelastic or the fish hook technique.

Cortical cleanup is typically performed with a Simcoe cannula (Figure 14). Using your paracentesis incision (or even two paracenteses 180 degrees apart) will give beginning surgeons a more stable anterior chamber and easier angles compared to going through the main incision.

IOL insertion and wound closure

Lens insertion is easiest with a three-piece acrylic lens, either by gently dialing it in with a Sinskey hook or dialing in the proximal haptic by supinating and then pronating the haptic into the bag with forceps. Due to the difficult visualization with some microscopes and/or a can opener capsulotomy, you

typically try not to use one-piece acrylic lenses as complete visualization of the haptics into the bag can be difficult.

You then remove the viscoelastic with a Simcoe cannula and hydrate all wounds. Most beginning surgeons place a suture to their scleral incision for their first few cases until they are comfortable with the security of their wounds. Conjunctival closure can be achieved with cautery, a stitch, or using the lid to reapproximate the conjunctiva. Most surgeons will then use intracameral antibiotics and subconjunctival steroids.

Why learn SICS?

Of the 36 million people in the world who are blind, 18 million of them are blind from cataracts (7). The cost of SICS can be as low as US \$15 (8), with broadly similar

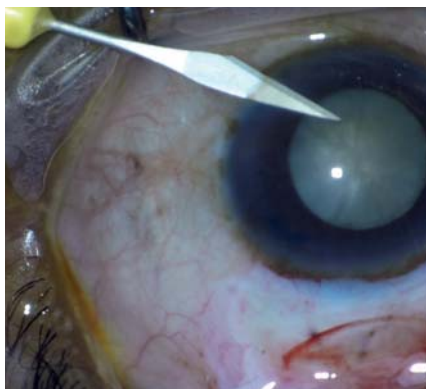
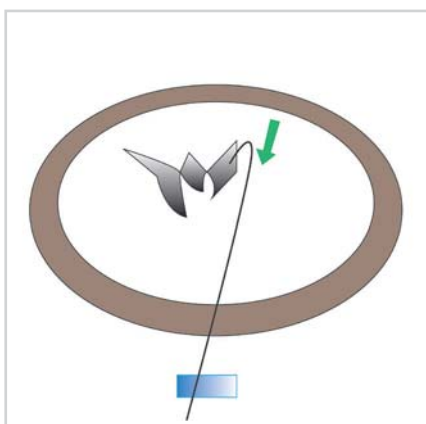


Figure 9. Paracentesis.



12. Can opener capsulotomy, with cystotome tearing peripherally and then centrally.

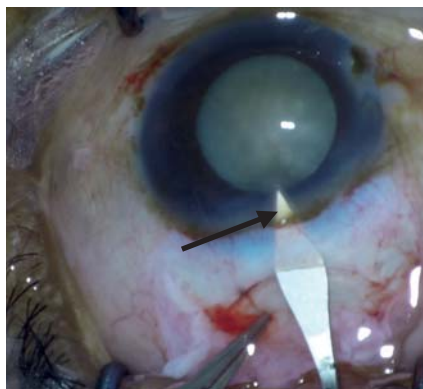


Figure 10. Microkeratome being used to enter the anterior chamber. Please note "dimple" the microkeratome makes, a sign the blade is in the correct plane and orientation.

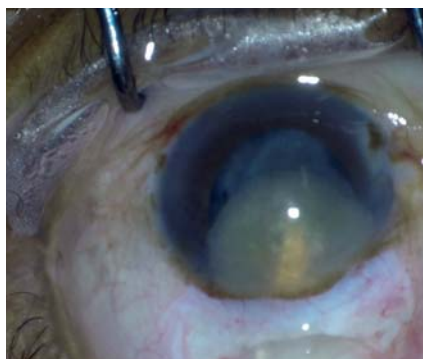

Figure 13. Lens removal.

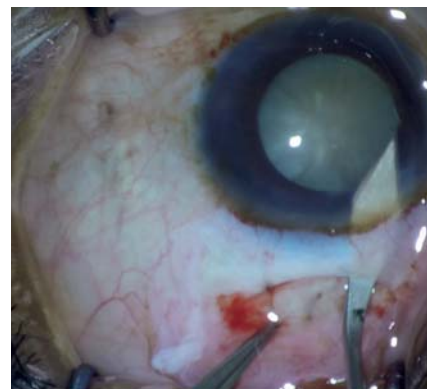


Figure 11. Fully opening scleral incision with the microkeratome blade.

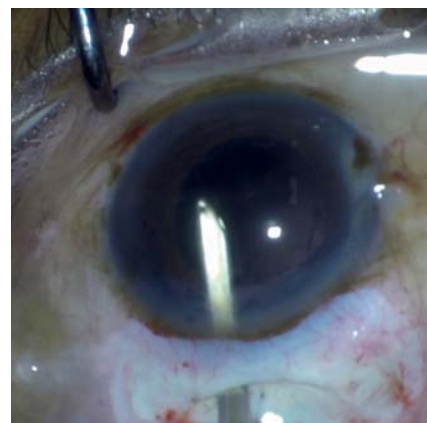


Figure 14. Cortical removal with Simcoe cannula.

outcomes to phacoemulsification. SICS is not only helpful to those looking to work in international ophthalmology but can also get you out of a difficult situation to achieve a good outcome in the clinic.

SICS might not quite fit into the adage of "see one, do one, teach one," but with a concerted effort and great mentors, it can certainly be learned to offer your patients with the hardest of cataracts another option that has been tried and proved the world over.

M. Scott Hickman is an ophthalmologist at Ad Astra Eye in Lawrence, Kansas, USA. He is involved in volunteer ophthalmology in the developing world, and in 2016 became the medical director of SEE International in Santa Barbara, California, a charity providing eye care throughout the world. In 2017 he

completed a Master's degree in Public Health for Eye Care at the London School of Hygiene and Tropical Medicine.

References

1. M Blumenthal et al., "Small-incision manual extracapsular cataract extraction using selective hydrodissection", *Ophthalmic Surg*, 23, 699–701 (1992). PMID: 1436973.
2. S Ruit et al., "An innovation in developing world cataract surgery: sutureless extracapsular cataract extraction with intraocular lens implantation", *Clin Exp Ophthalmol*, 28, 274–279 (2000). PMID: 11021556.
3. S Ruit et al., "A prospective randomized clinical trial of phacoemulsification vs manual sutureless small-incision extracapsular cataract surgery in Nepal", *Am J Ophthalmology*, 143, 32–38 (2007). PMID: 17188040.
4. VK Mallik et al., "Comparison of astigmatism following manual small incision cataract surgery: superior versus temporal approach", *Neaol J Ophthalmol*, 4, 54–58 (2012). PMID: 22343997.
5. G Tabin and M Feilmeier. "Cataract Surgery in the developing world", *AAO Focal Points 2011 Module*, eBook. Available at: <http://bit.ly/Tabin2011>.
6. BA Henderson. "Manual Small Incision Cataract Surgery", First edition, Springer International Publishing: 2016.
7. RRA Bourne et al., "Magnitude, temporal trends, and projections of the global prevalence of blindness and distance and near vision impairment: a systematic review and meta-analysis", *Lancet Glob Health*, 5, e888–e89 (2017). PMID: 28779882.
8. P Gogate et al., "Why do phacoemulsification? Manual small-incision cataract surgery is almost as effective, but less expensive.", *Ophthalmology*, 114, 965–968 (2007). PMID: 17296230.

Scleral Buckling 101

When primary scleral buckling should be considered – and how to succeed

By Alexander Ringeisen, Edwin Ryan and David Almeida

Rhegmatogenous retinal detachment (RRD) repair is one of the most common indications for retinal surgery. A multitude of anatomical presentations exist and therefore it is best treated with an individualized approach as opposed to a standardized procedure. Over the past 25 years, pars plana vitrectomy (PPV) has gained favor with vitreoretinal surgeons and is being used increasingly more than scleral buckling (SB) for RRD repair (1). Why has PPV gained favoritism? A variety of elements come into play, including the increased availability of small gauge

instrumentation, improved viewing and lighting systems, industry support, as well as economic factors. However, we believe that SB should remain the treatment of choice for certain types of primary RRDs, and that it should remain in the vitreoretinal surgeon's armamentarium for years to come. As such, it is imperative that current and future retinal fellows gain the skills necessary to perform the procedure.

SB was first described in 1949 by Ernst Custodis, and was further popularized by Charles Schepens and Harvey Lincoff in the 1950s. Over the past six decades, SB principles and techniques have remained relatively unchanged. The technique favorably alters the geometry and physiology of the eye to help close and maintain closure of retinal breaks. Inward indentation of the eye in conjunction with externally applied cryotherapy or laser photocoagulation creates a permanent adhesion between the neurosensory retina and the retinal pigment epithelium (RPE). Furthermore, SB-induced indentation helps overcome the forces tending to detach the retina, including cellular epiretinal proliferation and the

magnitude and direction of vitreous traction on the neurosensory retina (2). SB surgery is advantageous because, as well as treating existing retinal breaks, it also supports the vitreous base, which prevents new retinal tears (3). Additional advantages of SB over PPV include a lower incidence of cataract (which may help preserve accommodation in younger patients), fewer complications (such as endophthalmitis or choroidal hemorrhage), and no need for post-operative positioning or travel restrictions (4). But in this age of vitrectomy, which patients are best candidates for a primary scleral buckle?

Who and why?

In our experience, SB surgery should be strongly considered in patients presenting with specific scenarios, which are outlined below with our reasoning:

- i. Young, phakic patients with no posterior vitreous detachment.

At a Glance

- *We might be in the age of vitrectomy, but we believe that scleral buckling is the treatment of choice for certain retinal detachments*
- *But which patients are the best candidates for a primary scleral buckle and how should surgery be approached?*
- *We overview when primary buckling should be considered and provide guidance on which techniques will help success, as well as when to avoid a primary buckle*
- *Welcome to scleral buckling 101 for the senior ophthalmology resident and the junior retina fellow!*

SB Surgery in Seven Steps

1. Conjunctival peritomy and isolation of the rectus muscles.
2. External localization of all retinal breaks. Use indirect ophthalmoscopy and a scleral localizer to mark each break on the external sclera.
3. External drainage of subretinal fluid. Drainage of subretinal fluid should be performed in SB cases with a detachment that prevents adequate cryotherapy/photocoagulation treatment. This includes bullous RRD, chronic RRD, RRD with inferior retinal breaks, and in patients who are at risk of developing high intraocular pressure (for example, glaucoma or poor ocular perfusion).
4. Treatment of retinal breaks with cryotherapy and/or photocoagulation.
5. Placement of the SB.
6. Re-examination of retina with indirect ophthalmoscopy. Ensure that all retinal breaks are treated with cryotherapy/photocoagulation and supported by scleral indentation. Also, confirm perfusion of the central retinal artery.
7. Closure of Tenon's capsule and conjunctiva.

An online video resource overviewing the SB technique can be viewed at <http://bit.ly/SBSurgery>.

Why? Avoids cataract formation. Moreover, induction of a posterior vitreous detachment (PVD) during PPV can be technically challenging and create iatrogenic retinal breaks.

- ii. Retinal dialysis. Why? Typically there is no associated PVD with dialysis. Further, given its anterior location, it can be difficult to visualize and therefore perform adequate vitrectomy in the area of dialysis.
- iii. Very anterior break(s). Again, it is challenging to treat anterior retina with PPV.
- iv. Patients with extensive lattice or multiple retinal breaks at the vitreous base. SB provides 360° support to the vitreous base and peripheral retina thereby preventing future tears.
- v. High myopia with contact lens intolerance in phakic, middle-aged patients with minimal or no cataract. SB will not cause significant cataract acceleration or anisometropia; however, PPV will accelerate the formation of cataract, which could complicate cataract surgical planning, as the most attractive refractive outcomes will induce significant anisometropia.

How? Buckling 101

Regardless of the treatment modality used to treat RRD, the single most important factor is to detect and treat all retinal breaks and areas of vitreoretinal pathology. Various techniques and materials can be used in SB surgery but the two primary principles remain consistent: i) Close retinal breaks by apposing the RPE to the sensory retina, and ii) Reduce dynamic vitreoretinal traction at sites of vitreoretinal adhesion.

Worldwide, there is much variation in SB techniques and materials, but most procedures fall into one of three categories:

“In the age of vitrectomy, which patients are the best candidates for a primary scleral buckle?”

- i. Encircling circumferential buckle – 360° buckle. Used in cases with retinal breaks in three or more quadrants, diffuse retinal pathology (for example, lattice degeneration) or when there is concern about possible unidentified retinal breaks. These buckles are placed parallel to the limbus.
- ii. Segmental circumferential buckle. Used in cases where the retinal breaks span less than 6 clock hours and all breaks are identifiable and treatable with cryotherapy or laser retinopexy. These buckles are placed in parallel to the limbus.
- iii. Radial buckle. Used in cases with a single retinal break in an easily accessible location. Often for a large flap tear. These buckles are placed perpendicular to the limbus. A radial buckle may also be added to an encircling buckle in cases where the retinal tear is irregular or exhibits rolled edges.

When to avoid a primary buckle
Given the recent technological advances and excellent success rate of PPV, there are specific scenarios in which a SB is contraindicated:

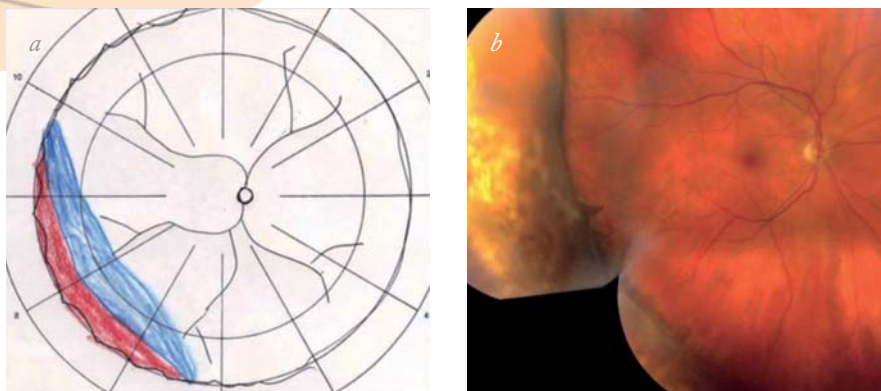
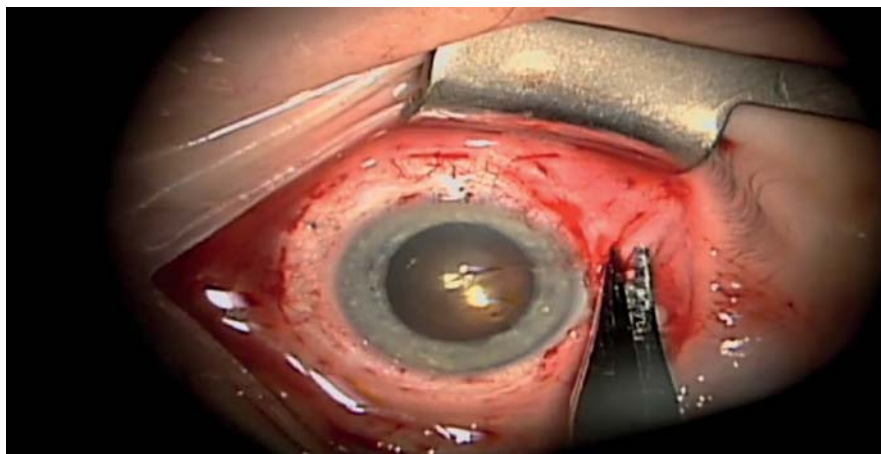


Figure 1. Drawing of a patient who had a traumatic dialysis (a) and post-operative fundus image showing the retina reattached (b). From <http://bit.ly/SBSurgery>.



Watch the SB instructional video online at: <http://bit.ly/SBSurgery>.

- i. Difficult visualization. Examination by indirect ophthalmoscopy is paramount during SB and thus any media opacities (for example, vitreous hemorrhage) limit the ability to treat with cryotherapy and/or laser.
- ii. Posterior breaks. Difficult for external drainage of fluid and placement of a SB.
- iii. Scleral thinning. Increased risk of globe rupture.
- iv. Significant vitreoretinal traction. In cases with tractional membranes (e.g. proliferative vitreoretinopathy, proliferative diabetic retinopathy), PPV is the procedure of choice.

In patients that are at high risk of developing proliferative vitreoretinopathy (PVR), it is appropriate to consider a combined PPV and SB procedure (5). A recent meta-analysis showed that the overall primary reattachment rate was significantly higher in PPV and SB than PPV alone, although the final reattachment rate was equally high in both groups (6). Therefore, we recommend consideration of a combined PPV and SB in patients who present with retinal detachment in two or more quadrants, retinal tears >1 clock hour, preoperative PVR, or vitreous hemorrhage.

Alexander Ringeisen is a first-year retina fellow at VitreoRetinal

Surgery, PA in Minneapolis, MN. Edwin Ryan is a vitreoretinal surgeon at VitreoRetinal Surgery, PA, and Associate Clinical Professor of Ophthalmology at the University of Minnesota. David Almeida is a vitreoretinal surgeon at VitreoRetinal Surgery, PA, Minneapolis, MN, USA. Almeida also writes a weekly blog, the Sunday Surgical Scrub, which can be found on his website davidalmeidamd.com.

References

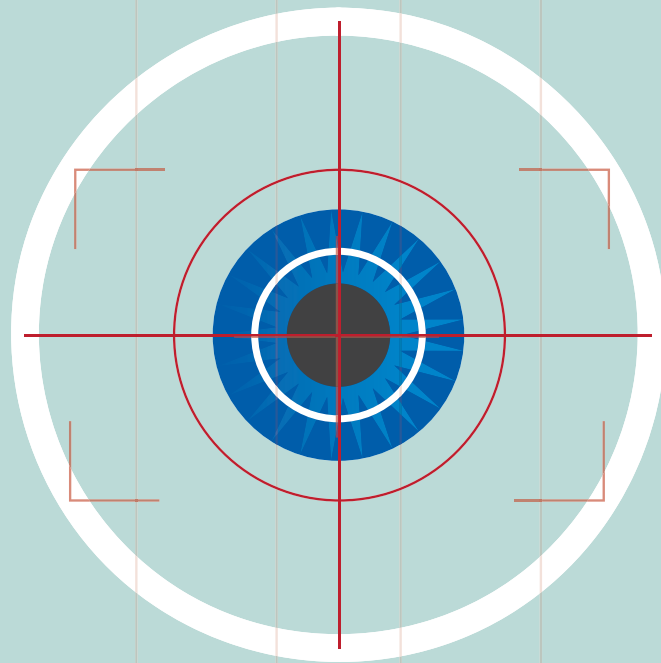
1. RA Adelman et al., "European vitreo-retinal society (EVRs) retinal detachment study group. Strategy for the management of complex retinal detachments: the European vitreo-retinal society retinal detachment study report 2", *Ophthalmology*, 120, 1809–1813 (2013). PMID: 23601805.
2. D Bloch et al., "The mechanism of the cryosurgical adhesion. III. Statistical analysis", *Am J Ophthalmol*, 71, 666–673 (1971). PMID: 5546312.
3. DJ D'Amico, "Clinical practice. Primary retinal detachment", *N Engl J Med*, 359, 2346–2354 (2008). PMID: 19038880.
4. JB Conart et al., "Results of scleral buckling for rhegmatogenous retinal detachment in phakic eyes", *J Fr Ophthalmol*, 36, 255–260 (2013). PMID: 22981521.
5. P Storey et al., "Wills PVR Study Group. Pars plana vitrectomy and scleral buckle versus pars plana vitrectomy alone for patients with rhegmatogenous retinal detachment at high risk for proliferative vitreoretinopathy", *Retina*, 34, 1945–1051 (2014). PMID: 24999720.
6. K Totsuka et al., "Supplemental scleral buckling in vitrectomy for the repair of retinal detachment: A systematic review of literature and meta-analysis", *Retina*, 35, 2423–2431 (2015). PMID: 26418447.

the
Ophthalmologist™

Presents

Modern LASIK Forum

Join John Marshall and a panel of world leading experts for a celebration of LASIK surgery:



John Kanellopoulos



Robert Maloney



Dan Reinstein



Stefanie Schmickler



Julian Stevens



Karl Stonecipher

Broadcast from The Royal Society, London
On Demand – <http://top.txp.to/MLForum>

Alcon A Novartis
Division


Johnson & Johnson VISION

ziemer

ZEISS

NextGen

*Research advances
Experimental treatments
Drug/device pipelines*



38–41

*Making the Subjective Objective
How ditching subjective measures for
objective metrics could improve visual
outcomes – and more – with IOLs.*

Making the Subjective Objective

So much of premium IOL selection comes down to chair time and questionnaires. But what if it didn't?

By Mark Hillen

Woe betide the surgeon with an unhappy patient – especially if that patient has spent a hefty sum of money on elective surgery to get there. Cataract and refractive surgeons describe such patients not as just ruining their day, but ruining their whole month.

One big challenge in refractive surgery is understanding what the patient wants – and then selecting the best course of action to meet that objective. Determining the correct target refraction (see Box 1) is critical, but there's more to it than that. For example, certain multifocal IOLs perform better in patients with small pupils and mesopic conditions than others; both toric

At a Glance

- *When selecting or recommending an IOL to a patient, surgeons try to get to know the patient through chair time and questionnaires*
- *Subjective assessments are not the best approach because patients can forget or misrepresent their visual requirements*
- *Truly and objectively assessing how patients use their vision day-to-day would allow surgeons to select the best IOL for their needs*
- *I overview the Visual Behavior Monitor, and how it can make the subjective objective*

multifocal and small-aperture optic IOLs can correct presbyopia and some amount of astigmatism. The problem is that no simple nomogram exists that can lead a surgeon to the best choice for the patient. It's why these surgeons spend a considerable amount of time discussing their patients' lifestyles – hobbies, work, whether they read the news on a newspaper or a phone screen, and even what time of day they drive – all to try to determine which option might be best for their patient. And that's before they start to make a call on a patient's personality type...

But there's a clear problem: it's all

subjective. A patient might say they do no close work, but then complain that they used to enjoy doing crossword puzzles or building 1:200 model airplanes after the surgery. They can be forgetful. They can be distracted. They might just be having a bad day when they are in the chair. Even if the surgeon knows the defocus curves of all IOLs on the market as well as the predicted refractive effects of all the surgical interventions at their disposal – and be experienced with them all – there's still a lot of guesswork. Surgeons are acutely aware of this and often decide to “play it safe” by offering a monofocal IOL rather





Box 1. Current methods of determining target refraction

Cataract Surgery

- Axial length (ocular biometry)
- Corneal refractive power (keratometry)
- IOL lens position prediction (regression formula)
- Subjective evaluated self-reported target refraction

Refractive surgery

- Subjective refraction
- Nomograms
- Subjective evaluated self-reported target refraction

The problem is that most of the methods listed above are inherently imprecise, which leads to deviation from the intended target refraction.

than a premium lens. Why risk having a disgruntled patient and the financial and reputational risks they bring? On the flipside, many patients who could benefit from a premium lens or other refractive procedure do not, which is a missed opportunity for surgeon and patient alike. Wouldn't it be nice to remove the subjective element from the process?

Smart objectivity

When you use a smartphone, you'll notice that the screen dims when you hold the device to your ear to make a call. Why? An infrared proximity

sensor. If you open your phone's built-in health app, you'll find that it has measured the number of steps you've taken that day. How has your phone become a pedometer? Your phone contains an accelerometer, gyroscope and magnetometer – it knows its orientation in all three dimensions at all times, and can detect the characteristic movement of each step. Finally, most smartphones can adjust their screen brightness to a level that's appropriate for the ambient lighting conditions – it dims in dark environments, and gets brighter when the surrounding area is well-lit. But the combination of proximity, orientation,

movement and ambient light sensors can be used to achieve something else – something that helps bring some objective metrics to the premium cataract surgeon's subjective dilemma.

It turns out that if you combine those three sensors on a small device that clips to a prospective patient's spectacles (Figure 1 – Vivior's Visual Behavior Monitor), you can mine the data that's recorded – and that includes the distance, duration, ambient lighting conditions, and even the angle of the patient's head – while the patient interacts with objects, people or performs tasks throughout their day (Figure 2; 1–3).



Figure 1. The Visual Behavior Monitor (Vivior AG, Zürich, Switzerland); a small device with distance, ambient light and orientation and motion sensors that clips onto a pair of spectacles.

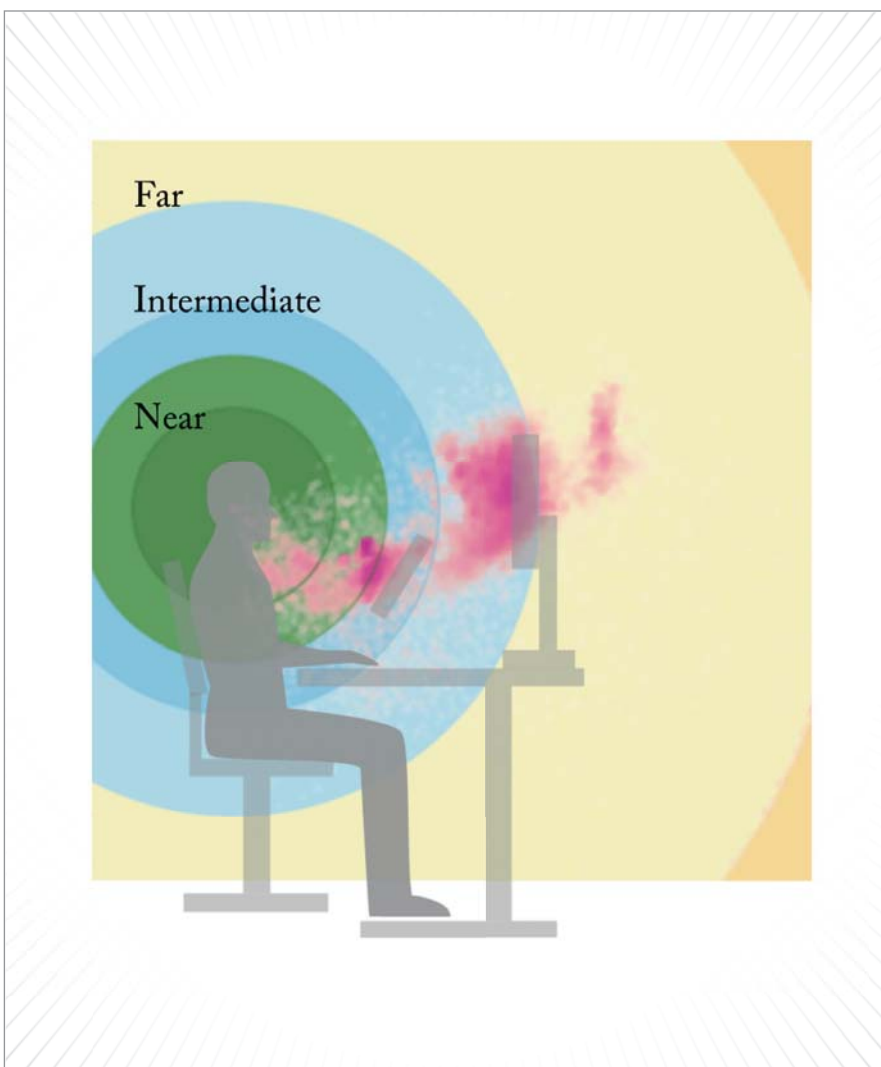


Figure 2. Illustration of a typical office working distance distribution map generated by the Visual Behavior Monitor.

“Devices like the Visual Behavior Monitor should also prove useful in helping patients understand their daily vision needs.”

The patient’s activities can be determined automatically through machine learning algorithms and this gives the surgeon the necessary information about the patient’s lifestyle. Crucially, such a device provides objective information on the patient’s lifestyle and visual needs that help the surgeon to choose the best treatment solutions (Figure 3). The objective device supersedes the subjective questionnaires and chair time.

A great deal of that chair time in cataract/refractive surgery involves patient education, because the decision on which surgical approach and product to use is a joint one. And so, devices like Vivior’s Visual Behavior Monitor should also prove useful in helping patients understand their daily vision needs – and, in doing so, increase their awareness and understanding of appropriate treatment options. Ultimately (or hopefully), patients will have more realistic expectations of what their personalized vision solution can achieve.

The move from subjective measures to objective metrics goes beyond aiding the selection of the optimal refractive solution

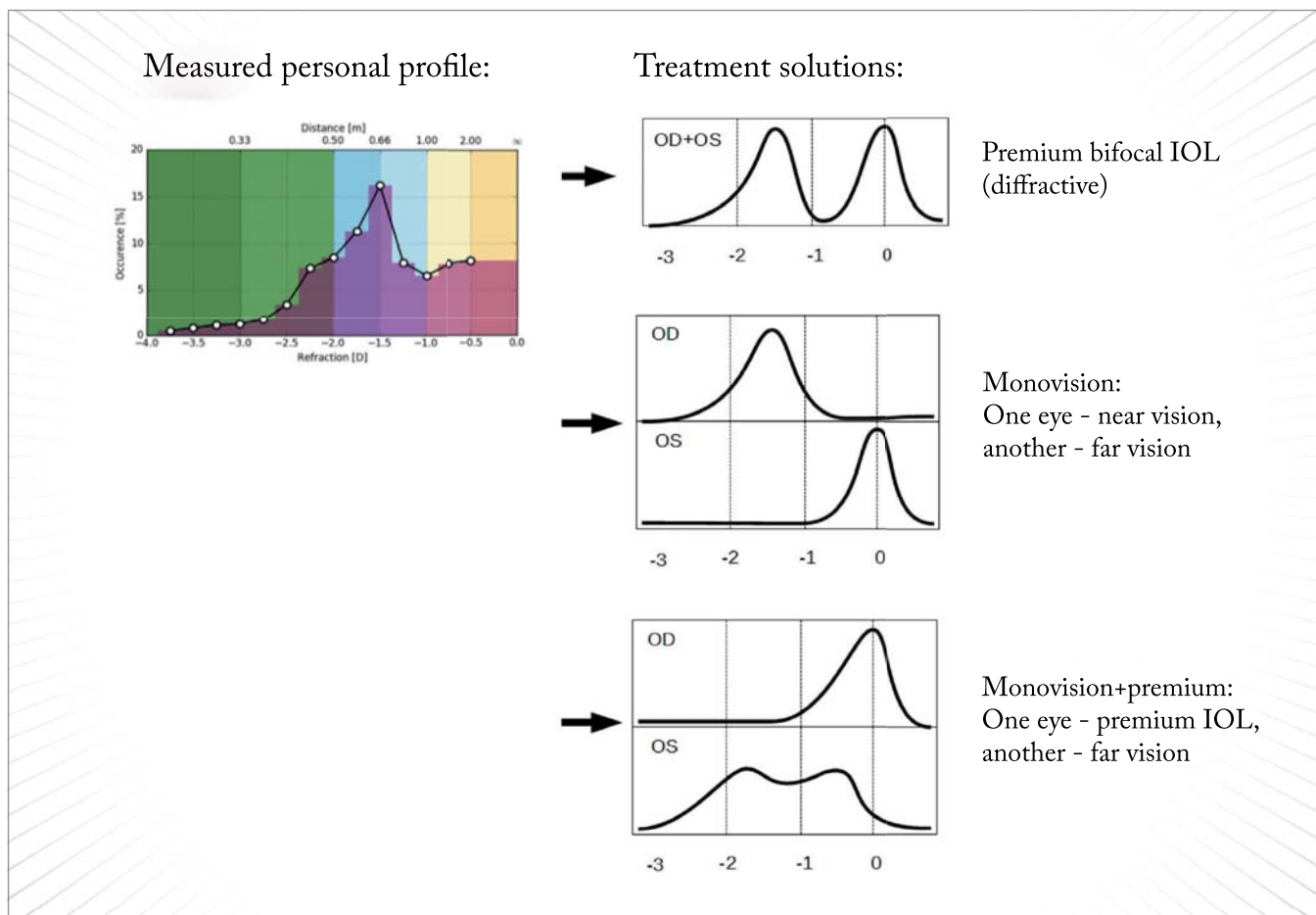


Figure 3. How the Visual Behavior Monitor data can be used to suggest treatment options for the patient based on their own activities.

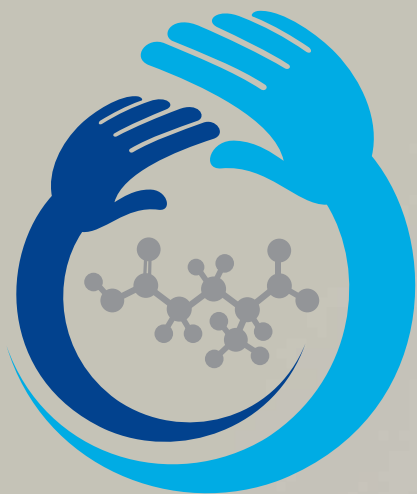*“Moving to
objective metrics
goes beyond
aiding the
selection
of the optimal
refractive solution.”*

based on patients’ needs – it could also help mitigate the legal risks involved with missed refractions and disgruntled patients.

Finally, the automated collection of objective data could feed into big data; the more data that’s collected, the more refined the automated predictions of activity become – and the more confident the surgeon can be with the predictions made by the system. If such automated solutions can expand the number of patients who can successfully undergo premium cataract/refractive surgery – and be happy with the outcome – it’s a win for everyone; the surgeon, the practice, the product manufacturers and, of course, the spectacle-free patient

References

1. A Cummings et al., “Patient Refractive Needs Assessed with Objective Measurements”, Presentation at the American Society of Cataract and Refractive Surgery (ASCRS), May 2017. Available at: bit.ly/vbmarthur.
2. M Mrochen, et al., “Objective evaluation of patients’ visual behavioural pattern for cataract surgery planning”, Presentation at the European Society of Cataract & Refractive Surgeons (ESCRS) October 2017. Available at: bit.ly/vbmmich.
3. M Mrochen et al., “Planning the individual refractive correction for cataract patients based on objectively measured refraction profile”, Presentation at the European Society of Cataract & Refractive Surgeons (ESCRS) October 2017. Available at: bit.ly/vmbtop.



HUMANITY IN
SCIENCE AWARD

the **Analytical Scientist**

In partnership with



Richard Jähnke

Meet the Winner

Richard Jähnke

Richard Jähnke from the Global Pharma Health Fund (GPHF) has received the 2017 Humanity in Science Award for “development and continuous improvement of GPHF Minilab™ (www.gphf.org), which represents a breakthrough for the rapid and inexpensive identification of substandard and falsified medicines in low- and middle income countries in Africa, Asia and Latin America”.

Richard received his award at a special jubilee reception in Berlin, Germany on October 2, 2017 hosted by KNAUER to celebrate the company's 55th birthday this year. Richard's work will feature in an upcoming issue of The Analytical Scientist.

Could it be you in 2018?

Analytical science has been at the heart of many scientific breakthroughs that have helped to improve people's lives worldwide. And yet analytical scientists rarely receive fanfare for their humble but life-changing work. The Humanity in Science Award was launched to recognize and reward analytical scientists who are changing lives for the better.

Has your own work had a positive impact on people's health and wellbeing? Details of the 2018 Humanity in Science Award will be announced soon.



@Humanityaward



Humanity in Science Award

www.humanityinscienceaward.com

Profession

*Your career
Your business
Your life*



44–45

Is Twitter Dead?

Pavan Angadi and Robert F. Melendez look into ophthalmologists' Twitter use and offer their tips for social media success...

46–47

Decision Diagnosis

Are you guilty of procrastinating? David Almeida shares his advice on making the right decision without delay!

Is Twitter Dead?

To find out, we delved into the usage rates and trends among ophthalmologists...

By Pavan Angadi and Robert F. Melendez

Back in 2006, the microblogging website Twitter hatched. Despite a period of rapid growth in user numbers – particularly around 2009 and 2010 – usage today is declining (1). But does this trend of declining Twitter use also apply to tweeting ophthalmologists?

Following trends?

In 2016, Christiansen et al. (2) studied Twitter activity at the 2014 and 2015 annual AAO meetings, and found that there was a 43 percent increase in the numbers of ophthalmologists tweeting at the 2015 meeting. The majority of the tweets were centered on the meeting (66 percent) and tweeted by ophthalmologists at earlier career stages (63 percent; trainee or fewer than 10 years' experience). Not only that, the number of impressions – the amount of people seeing those tweets – generated during the 2014 meeting (23.7 million) was more than 7.5 times greater than the

impressions at a large emergency medicine conference (3.12 million), despite a similar number of tweets. What does this tell us? Ophthalmologists appear to have more active followers on Twitter than our emergency medicine colleagues.

Our study was designed to track ophthalmologists' Twitter usage in 2016 and 2017, and collected data at two individual time points: May 27 and 28, 2016; and May 6 and 7, 2017 (3). Ophthalmologist accounts were identified using keywords such as 'ophthalmologist' and 'eye surgeon'; 'eye doctor' was not used as it was difficult to differentiate between ophthalmologists and optometrists. To ensure that only active ophthalmology users were included in our study, we excluded those who hadn't tweeted for 30 days as well as those who had no profile picture. In our analysis, we identified a surprisingly low number of active users worldwide – 138 in 2016 and 169 in 2017 – and that only one ophthalmologist joined twitter as an active user in 2017. Sixty percent of users were located in the US, with the majority residing on the east coast and in California. Analyzing users by subspecialty, the distributions were similar in both 2016 and 2017, with comprehensive ophthalmologists making up the largest volume by far, followed by retina specialists and residents (Figure 1a). Between 2016 and 2017, tweets, followers, and accounts followed by the user had all increased (56.9, 8.0 and 39.1 percent, respectively). Average tweets per month by users has also increased (38.6 percent) – although the potential impact of the ASCRS and ARVO annual meetings (which took place in May 2017) is not known. But despite the increased activity of ophthalmologists between 2016 and 2017, we found that the number of new users joining Twitter per year has actually decreased (Figure 1b). The upshot? The numbers of ophthalmologists joining Twitter might be decreasing, but the activity of users is increasing.

An ongoing education

So is Twitter dead? No. Twitter might have some flaws (See 'Five Things We Want to See from Twitter'), but our results have shown that despite declining growth, Twitter still represents a great opportunity for ophthalmologists to educate, advocate, fundraise, mentor and market. The majority of the biggest names in medicine and other industries are on Twitter, including world leaders, celebrities and heads of companies. It offers a great opportunity to build a name for yourself and interact with your peers, as well as a platform for rapid dissemination of information.

We want to see more ophthalmologists on Twitter, but, more importantly, we want more effective Twitter users, so we would like to educate the existing flock. It can all start with something as simple as your username and profile. Our study identified a surprisingly small number of ophthalmologists actively using Twitter, but we know there are more out there who weren't picked up in our study. Why? Because he or she simply don't identify themselves as ophthalmologists on their profile, which is to their detriment; identifying yourself professionally as an ophthalmologist, eye surgeon and/or MD in your username and profile brings credibility. It gives you the authority to share information, and when you do share information – whether on dry eye or issues with contact lenses – people might be more likely to read it and be more trusting. Furthermore, the username itself should be easy for others to read and remember; the majority of people use social media through their mobile devices, so it is best to have a username without special characters.

Your Twitter activity should also be considered. Every user of social media is either a consumer or a producer – either sucking up information or generating content. We think most ophthalmologists are consumers because they don't generate much content, but if you are actively generating content on Twitter, it's good

At a Glance

- *Twitter is a brilliant platform where vast amounts of information are disseminated every day*
- *Worldwide, Twitter use is declining – but are ophthalmologists following that trend?*
- *Analyzing Twitter usage between 2016 and 2017, we found that although the number of users joining the service was in decline, activity of existing users has increased*
- *We summarize our findings and offer our advice for ophthalmologists on social media.*

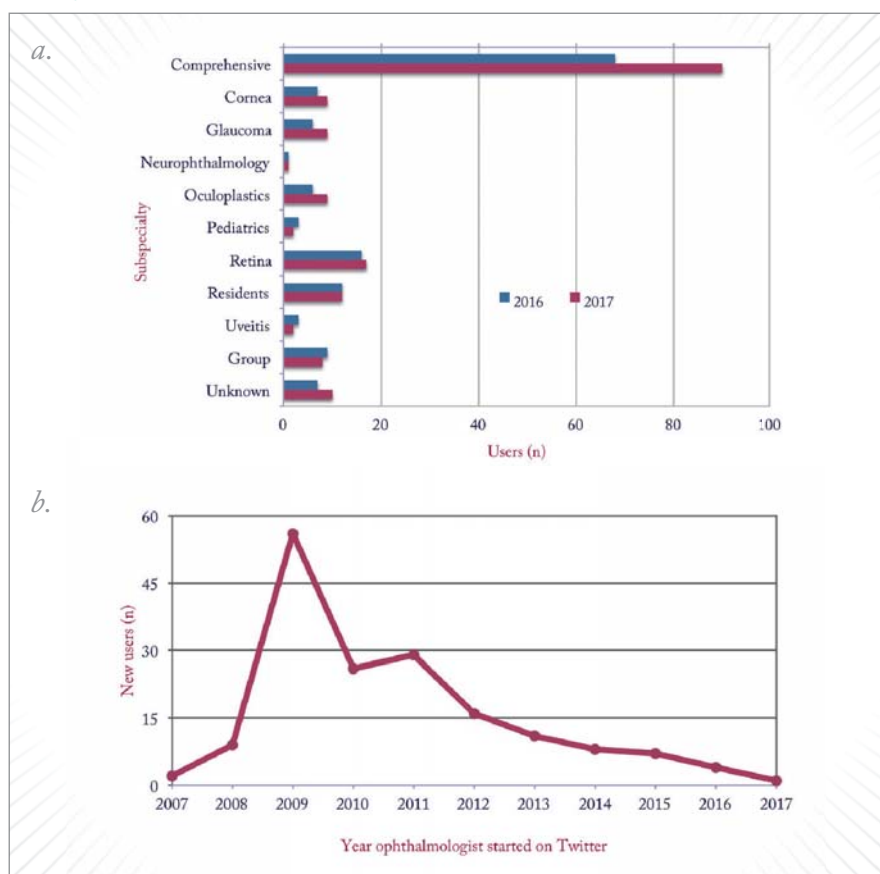


Figure 1. Ophthalmologist Twitter users by (a) subspecialty, and (b) the year they joined Twitter (based on May 6–7 2017 tweets) – note, the number of new (ophthalmologist) Twitter has declined each year since 2011.

to consider what you are posting and why. Is your content mostly personal, social or professional? What are you highlighting from a professional standpoint? How effective is your content at reaching followers? We advise a more strategic approach to managing your account. What are your core competencies? Talking about leadership, ophthalmology or research all work well – but it's good to have a focus. Effectively using hashtags and tagging other users to promote engagement is also important, of course.

We're passionate about effective social media usage because, whether you like it or not, you will have an online footprint, so you should take control of the content that people can find. Whether you are a consumer or a producer, your profile should be professional and free of personal

information – and you should ensure that your activity is in line with how you wish to be perceived by your followers. Most importantly, don't be afraid to take the opportunity!

Pavan Angadi is an ophthalmology resident at Howard University Hospital, Department of Ophthalmology, Washington D.C.

Robert F. Melendez is an ophthalmologist at Eye Associates of New Mexico, Albuquerque, and Assistant Clinical Professor in the Department of Surgery/ Division of Ophthalmology at the University of New Mexico in Albuquerque. He is also executive director of The Juliette RP Vision Foundation and Founder of Social Media Page Creators.

Five things we want to see from Twitter

1. The ability to edit tweets once they have been posted.
2. A reminder of where users left last time, so that when they log back on, they may easily continue from where they were before (if they wish).
3. Twitter recommendations personalized to users based on their previous activity.
4. A 'weeding out' process for followers. We would recommend that Twitter could enlist a system where users can get a notification informing them if a follower has become inactive, and an option to unfollow them. This would also provide Twitter with an opportunity to alert the user they have been unfollowed and invite them back.
5. Better integration with other platforms, such as LinkedIn, to facilitate easier tagging of users from other platforms.

References

1. Statista.com, "Annual Twitter user growth rate worldwide from 2015 to 2020". Available at: <http://bit.ly/2CabDvS>. Accessed: December 15, 2017.
2. SM Christiansen et al., "Twitter at the 2014 and 2015 annual meetings of the American Academy of Ophthalmology", *Ophthalmol*, 123, 1835–1837 (2016). PMID: 27067923.
3. P Angadi et al. "Is Twitter dead? Usage rates and trends among ophthalmologists". Presentation at the annual meeting of the American Academy of Ophthalmology, November 11–14, 2017; New Orleans, USA.

Decision Diagnosis

Making a PACT to avoid decision procrastination

By David Almeida

We are used to having everything at our fingertips these days, but the endless deluge of information minimizes our ability to process it. It creates a weakened state of critical thinking. A never-ending cacophony of notifications, messages and other electronic distractions has reduced our attention span and our decision-making ability to new lows: we have reached a calamity of inaction. We procrastinate and put off for tomorrow what we should be doing today, and this has an overwhelming negative impact on our ability to solve the problems we face.

Over the years, I have noticed the common difficulties people face with making decisions. As a vitreoretinal surgeon with a background in both research and business, I decided to approach the common struggles of decision making with a framework that blends both the spheres of medicine and management.

At a Glance

- Too much information bombarding us – emails, notifications, texts, calls – can weaken our critical thinking
- Procrastination is the first step on the path towards the calamity of inaction
- Delaying decisions can have serious consequences like missed opportunities, poorer outcomes
- Taking a “Decision Diagnosis” approach will give you an antidote to decision malaise – and allow you to come to fruitful and focused decisions

The goal is an approach that allows one to become unstuck from mediocrity and procrastination, and head towards effective personal and professional strategy. Whether we like it or not, we must all make decisions; delaying them results in significant negative consequences, including the loss of precious time, missed opportunities, and the consequences of poor decisions.

*“Plan and execute;
but above all – do it
passionately —
therein lies both your
path and purpose.”*

My first pearl of wisdom? You can’t make successful decisions, if you don’t know what those decisions are asking of you. In my book, *Decision Diagnosis*, there are seven antidotes to decision malaise that allow you to uncover what you need to know and understand about the situation at hand to arrive at fruitful and focused decisions. Via brokering of economics theories, the scientific method, and a surgical approach to medical problems, we can consistently arrive at clear methods to diagnose decisions.

My years as a physician and surgeon have given me insight into the diagnosis of complex diseases. I have learned that they can appear in many ways. Sometimes, a patient’s disease presents itself in a textbook way, making the diagnosis and treatment straightforward. However, most of the time, diseases present in convoluted manners, leaving doctors confused, with the possibility of complications with catastrophic implications.

Physicians and surgeons routinely go through seven attributes of a medical problem to tease out the pertinent positives and negatives from a patient, to arrive at the right diagnosis, and manage the patient with the correct treatment. In my book, I hybridize this medical technique normally used for complex diagnoses with my work in research and business leadership to create seven antidotes to decision procrastination.

When you apply this framework, I believe it will provide you with useful insights. Most importantly of all, it will aid a greater understanding, clarity, and focus for strategy and decision-making. The seven antidotes are all about uncovering the relevant factors of your decisions for success. Indeed, there are seven characteristics that you need to evaluate and judge to enhance your ability to be efficient and successful in decision-making:

- character
- setting
- timing
- quality
- quantity
- aggravating factors
- alleviating factors.

Whether it is for personal or professional decisions, I believe this construct will facilitate your success and improve your strategic and executive function.

If you are struggling with decision making, then *Decision Diagnosis* can help you make a PACT.

- Practice: Practice makes permanence. Practice with purpose and passion and it will transform and allow for positive development. You need to break the cycle of mindless practice and instill passion and purpose in the skills you hope to hone.
- Assess the problem: Identify the



character of the conflict. Ask open-ended questions like who, what, when, where and why? Without knowing the character of the problem, the best decision may elude you.

- Collect information: Who are the people, places and things relevant to your decision?
- Triage: Define how much time you have to make the decision in question. Triage your decision to assess if you need to resolve it right away or if it can be dealt with as a lower priority?

After coming to terms with the relevant aspects of a decision, it is time to execute! Strategy is loosely defined as some series of actions we employ to achieve a desirable outcome, and a defined framework is

part of a coherent strategy. Ultimately, your strategy must achieve your goals – otherwise, you must consider switching strategies. But what makes a strategy successful? My two tenets of any successful strategy are planning and execution. I plan like an economist, but I execute like a surgeon. In planning, you must employ some analysis. Whether it's a simple pro/con list, the PACT framework, or a formal SWOT analysis, you must bring your decision out of your personal vacuum and into context and consequence. But, when you have done all the planning, you must go out and execute it – just like when I perform a surgery, there is no time for uneasiness or hesitation.

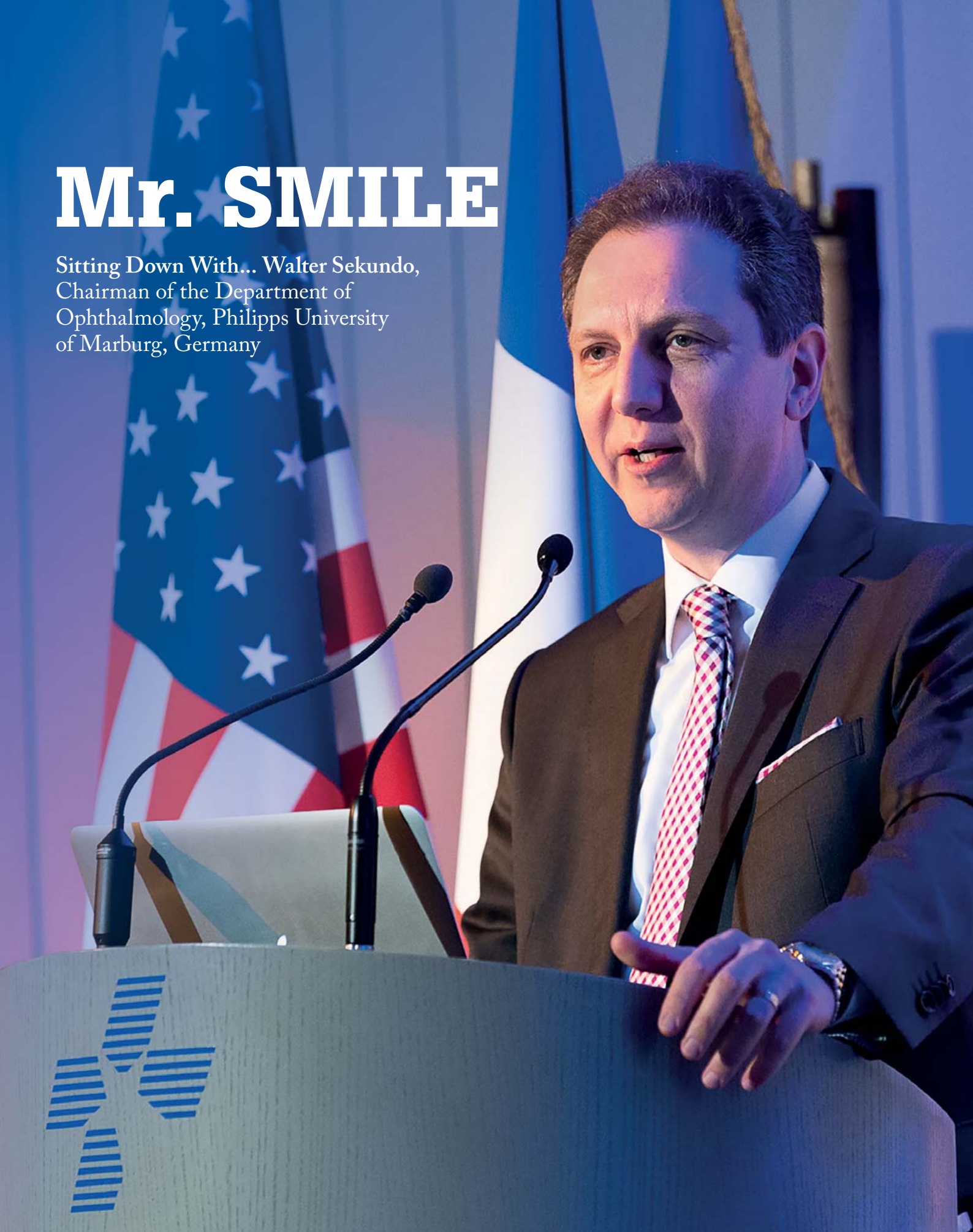A good decision today is always preferred over a perfect decision tomorrow. So, no matter what goal you are trying to achieve,

make a PACT, then plan and execute. Don't let time spent on one deviate the path for the other.

David Almeida holds an MD from Queen's University in Kingston, Ontario, an MBA from George Washington University School of Business in Washington, D.C., and a PhD in Pharmaceutical Drug Research from the University of Szeged. A 2017 The Ophthalmologist Power List Rising Star, he's not only a practicing surgeon with Vitreoretinal Surgery, PA in Minneapolis-St. Paul, Minnesota, but also cofounder of the pharmaceutical company Citrus Therapeutics. His best-selling book, Decision Diagnosis: Seven Antidotes to Decision Procrastination, blends the spheres of medicine, science, business, and leadership to present new concepts and strategies for successful decision making.

Mr. SMILE

Sitting Down With... Walter Sekundo,
Chairman of the Department of
Ophthalmology, Philipps University
of Marburg, Germany



What led you to ophthalmology?

I always wanted to be a general surgeon, but because of a spinal injury I suffered when I was 13 years old, I realized in medical school that I wouldn't be able to stand at an operating table for hours and hours in the long term. How I actually ended up in ophthalmology was quite coincidental. I partially studied in the US, starting with internal medicine at Tulane University, which I found too boring because I like to do something with my hands. So then I did OB-GYN, but I only enjoyed the obstetric parts. I asked the secretary if there were any other clerkships, and it turned out that nobody had applied for an ophthalmology clerkship. A friend of mine recommended Louisiana State University – at the time, Herbert Kaufman was Chairman and Marguerite McDonald was an Associate Professor. Later, my first post-graduate fellowship at the Tennent's Institute of Ophthalmology with Bill Lee and Colin Kirkness in Glasgow, UK, got me specifically interested in cornea and anterior segment.

And refractive surgery?

I started doing intraocular surgery in my second year of residency – which is quite early. But when I went to the University of Marburg as a consultant and started refractive surgery, I felt that I needed to catch up a bit. So I applied for a refractive and corneal surgery fellowship at Moorfields with Julian Stevens. I learnt a lot from Julian, and when I returned to Germany, I moved on very quickly and also obtained a PhD.

What's the story behind developing SMILE?

I was approached by Zeiss because of my academic interest in refractive surgery. After initial animal studies, Marcus Blum and I moved into patients.

*“I really want
to see a few more
companies
come to the market
with SMILE,
because this will
drive the market
forwards.”*

At that stage, it wasn't the familiar laser setup available today – it was a very simple box. The first procedure we performed was FLEEx – femtosecond lenticule extraction with a flap. We presented results from the first 10 eyes at the 2006 AAO meeting in Las Vegas – and people didn't believe us. SMILE was a further development of the FLEEx procedure. We performed many studies involving the flap and incision locations, and performed the procedure in around 200 eyes in one year. Zeiss were keen to have more patients treated – and more data – so they brought Rupal Shah on board. Within three months she had performed the surgery on around 500 eyes. Now, there have been over one million registered procedures performed worldwide. We carried on researching to get to the stage we are the moment, and we are still doing a great deal of research, including biomechanical experimental work and surgical prospective studies, among those hyperopic SMILE. And that's how I became “Mr. SMILE”.

Were there any interesting challenges in SMILE development?

I began studies with cadaver pig eyes, but when I moved to rabbits it didn't work well. As a trained eye pathologist, I studied their corneas and realized that the rabbit cornea had an entirely different structure compared with human cornea. So we decided to use piglets – but they grow incredibly fast, becoming huge by three months follow-up. Because of the issues with my back, Zeiss actually hired two strong veterinarian nurses to carry pigs for experiments! They also hired a veterinarian anesthesiologist so we could examine them. In the end, it worked very well in pigs...

What do you think the refractive surgery market will look like in 10 years' time?

I really want to see a few more companies come to the market with SMILE, because this will drive the market forwards. There is no question that we need better lasers for it to be more accepted within the ophthalmic community. I do believe that SMILE will grow, but I do not believe that it will replace femto-LASIK entirely. I think in the long-term we will have SMILE as a standard procedure, with femto-LASIK and PRK as additional procedures for certain indications. But at the end of the day, the armamentarium we have becomes larger. Just like IOLs, we try to select the best possible procedure for the patient. And this is what makes refractive surgery so different from the way it was performed in the early 90s. In those days, we were looking at just reducing diopters. Now, we also want to deliver a high quality of vision.

I also think IOLs will improve. When you look at the development of cataract surgery, the major developments are better lenses and better optics. In 10 years' time, I hope we'll see a real accommodating IOL – this would be



a significant breakthrough. Once we have a real accommodating IOL, it will change the entire refractive surgery market; we'll be able to approach emmetropia and presbyopia. And we might move to work more inside of the eye rather than performing surgery on the surface.

Any advice for the younger Walter Sekundo?

Simply to do everything the way I did it – I have no regrets. I was lucky to be in the right place at the right time. I would also say that it is important to benefit from what you do and to be able to carry on professionally. When people at our institute obtain PhDs and professorships, I usually tell them to remember that they didn't achieve these

things to treat only private patients – there are other obligations, such as passing on the knowledge acquired over the years to the next generation and

“Once we have a real accommodating IOL, it will change the entire refractive surgery market.”

actively contributing to the progress of our profession by high quality research.

Walter Sekundo has been Chairman of the Department of Ophthalmology at Philips University of Marburg, Germany, since December 2008. In 2008, Sekundo and his colleague Marcus Blum were awarded first prize by the American Society of Cataract and Refractive Surgeons for their work in the field of refractive surgery. In 2010, both Sekundo and Blum were awarded the Leonhard Klein Prize for their work on FLEx. Sekundo has authored over 100 publications on refractive surgery, and has edited the textbook “Small Incision Lenticule Extraction (SMILE): Principles, Techniques, Complication Management and Future Concepts”.

BRIEF SUMMARY OF PRESCRIBING INFORMATION

This Brief Summary does not include all the information needed to use VYZULTA safely and effectively. See full Prescribing Information for VYZULTA.

VYZULTA™ (latanoprostene bunod ophthalmic solution), 0.024%, for topical ophthalmic use.

Initial U.S. Approval: 2017

1 INDICATIONS AND USAGE

VYZULTA™ (latanoprostene bunod ophthalmic solution) 0.024% is indicated for the reduction of intraocular pressure (IOP) in patients with open-angle glaucoma or ocular hypertension.

4 CONTRAINDICATIONS

None

5 WARNINGS AND PRECAUTIONS

5.1 Pigmentation

VYZULTA™ (latanoprostene bunod ophthalmic solution), 0.024% may cause changes to pigmented tissues. The most frequently reported changes with prostaglandin analogs have been increased pigmentation of the iris and periorbital tissue (eyelid).

Pigmentation is expected to increase as long as latanoprostene bunod ophthalmic solution is administered. The pigmentation change is due to increased melanin content in the melanocytes rather than to an increase in the number of melanocytes. After discontinuation of VYZULTA, pigmentation of the iris is likely to be permanent, while pigmentation of the periorbital tissue and eyelash changes are likely to be reversible in most patients. Patients who receive prostaglandin analogs, including VYZULTA, should be informed of the possibility of increased pigmentation, including permanent changes. The long-term effects of increased pigmentation are not known.

Iris color change may not be noticeable for several months to years. Typically, the brown pigmentation around the pupil spreads concentrically towards the periphery of the iris and the entire iris or parts of the iris become more brownish. Neither nevi nor freckles of the iris appear to be affected by treatment. While treatment with VYZULTA™ (latanoprostene bunod ophthalmic solution), 0.024% can be continued in patients who develop noticeably increased iris pigmentation, these patients should be examined regularly [see Patient Counseling Information (17) in full Prescribing Information].

5.2 Eyelash Changes

VYZULTA may gradually change eyelashes and vellus hair in the treated eye. These changes include increased length, thickness, and the number of lashes or hairs. Eyelash changes are usually reversible upon discontinuation of treatment.

5.3 Intraocular Inflammation

VYZULTA should be used with caution in patients with a history of intraocular inflammation (iritis/uveitis) and should generally not be used in patients with active intraocular inflammation as it may exacerbate this condition.

5.4 Macular Edema

Macular edema, including cystoid macular edema, has been reported during treatment with prostaglandin analogs. VYZULTA should be used with caution in aphakic patients, in pseudophakic patients with a torn posterior lens capsule, or in patients with known risk factors for macular edema.

5.5 Bacterial Keratitis

There have been reports of bacterial keratitis associated with the use of multiple-dose containers of topical ophthalmic products. These containers had been inadvertently contaminated by patients who, in most cases, had a concurrent corneal disease or a disruption of the ocular epithelial surface.

5.6 Use with Contact Lens

Contact lenses should be removed prior to the administration of VYZULTA because this product contains benzalkonium chloride. Lenses may be reinserted 15 minutes after administration.

6 ADVERSE REACTIONS

The following adverse reactions are described in the Warnings and Precautions section: pigmentation (5.1), eyelash changes (5.2), intraocular inflammation (5.3), macular edema (5.4), bacterial keratitis (5.5), use with contact lens (5.6).

6.1 Clinical Trials Experience

Because clinical trials are conducted under widely varying conditions, adverse reaction rates observed in the clinical trials of a drug cannot be directly compared to rates in the clinical trials of another drug and may not reflect the rates observed in practice.

VYZULTA was evaluated in 811 patients in 2 controlled clinical trials of up to 12 months duration. The most common ocular adverse reactions observed in patients treated with latanoprostene bunod were: conjunctival hyperemia (6%), eye irritation (4%), eye pain (3%), and instillation site pain (2%). Approximately 0.6% of patients discontinued therapy due to ocular adverse reactions including ocular hyperemia, conjunctival irritation, eye irritation, eye pain, conjunctival edema, vision blurred, punctate keratitis and foreign body sensation.

8 USE IN SPECIFIC POPULATIONS

8.1 Pregnancy

Risk Summary

There are no available human data for the use of VYZULTA during pregnancy to inform any drug associated risks.

Latanoprostene bunod has caused miscarriages, abortion, and fetal harm in rabbits. Latanoprostene bunod was shown to be abortifacient and teratogenic when administered intravenously (IV) to pregnant rabbits at exposures \geq 0.28 times the clinical dose.

Doses \geq 20 μ g/kg/day (23 times the clinical dose) produced 100% embryofetal lethality. Structural abnormalities observed in rabbit fetuses included anomalies of the great vessels and aortic arch vessels, domed head, sternebral and vertebral skeletal anomalies, limb hyperextension and malrotation, abdominal distention and edema. Latanoprostene bunod was not teratogenic in the rat when administered IV at 150 mcg/kg/day (87 times the clinical dose) [see Data].

The background risk of major birth defects and miscarriage for the indicated population is unknown. However, the background risk in the U.S. general population of major birth defects is 2 to 4%, and of miscarriage is 15 to 20%, of clinically recognized pregnancies.

Data

Animal Data

Embryofetal studies were conducted in pregnant rabbits administered latanoprostene bunod daily by intravenous injection on gestation days 7 through 19, to target the period of organogenesis. The doses administered ranged from 0.24 to 80 mcg/kg/day. Abortion occurred at doses \geq 0.24 mcg/kg/day latanoprostene bunod (0.28 times the clinical dose, on a body surface area basis, assuming 100% absorption). Embryofetal lethality (resorption) was increased in latanoprostene bunod treatment groups, as evidenced by increases in early resorptions at doses \geq 0.24 mcg/kg/day and late resorptions at doses \geq 6 mcg/kg/day (approximately 7 times the clinical dose). No fetuses survived in any rabbit pregnancy at doses of 20 mcg/kg/day (23 times the clinical dose) or greater. Latanoprostene bunod produced structural abnormalities at doses \geq 0.24 mcg/kg/day (0.28 times the clinical dose). Malformations included anomalies of sternum, coarctation of the aorta with pulmonary trunk dilation, retroesophageal subclavian artery with absent brachiocephalic artery, domed head, forepaw hyperextension and hindlimb malrotation, abdominal distention/edema, and missing/fused caudal vertebrae.

An embryofetal study was conducted in pregnant rats administered latanoprostene bunod daily by intravenous injection on gestation days 7 through 17, to target the period of organogenesis. The doses administered ranged from 150 to 1500 mcg/kg/day. Maternal toxicity was produced at 1500 mcg/kg/day (870 times the clinical dose, on a body surface area basis, assuming 100% absorption), as evidenced by reduced maternal weight gain. Embryofetal lethality (resorption and fetal death) and structural anomalies were produced at doses \geq 300 mcg/kg/day (174 times the clinical dose). Malformations included anomalies of the sternum, domed head, forepaw hyperextension and hindlimb malrotation, vertebral anomalies and delayed ossification of distal limb bones. A no observed adverse effect level (NOAEL) was established at 150 mcg/kg/day (87 times the clinical dose) in this study.

8.2 Lactation

Risk Summary

There are no data on the presence of VYZULTA in human milk, the effects on the breastfed infant, or the effects on milk production. The developmental and health benefits of breastfeeding should be considered, along with the mother's clinical need for VYZULTA, and any potential adverse effects on the breastfed infant from VYZULTA.

8.4 Pediatric Use

Use in pediatric patients aged 16 years and younger is not recommended because of potential safety concerns related to increased pigmentation following long-term chronic use.

8.5 Geriatric Use

No overall clinical differences in safety or effectiveness have been observed between elderly and other adult patients.

13 NONCLINICAL TOXICOLOGY

13.1 Carcinogenesis, Mutagenesis, Impairment of Fertility

Latanoprostene bunod was not mutagenic in bacteria and did not induce micronuclei formation in the *in vivo* rat bone marrow micronucleus assay. Chromosomal aberrations were observed *in vitro* with human lymphocytes in the absence of metabolic activation.

Latanoprostene bunod has not been tested for carcinogenic activity in long-term animal studies. Latanoprost acid is a main metabolite of latanoprostene bunod. Exposure of rats and mice to latanoprost acid, resulting from oral dosing with latanoprost in lifetime rodent bioassays, was not carcinogenic.

Fertility studies have not been conducted with latanoprostene bunod. The potential to impact fertility can be partially characterized by exposure to latanoprost acid, a common metabolite of both latanoprostene bunod and latanoprost. Latanoprost acid has not been found to have any effect on male or female fertility in animal studies.

13.2 Animal Toxicology and/or Pharmacology

A 9-month toxicology study administered topical ocular doses of latanoprostene bunod to one eye of cynomolgus monkeys: control (vehicle only), one drop of 0.024% bid, one drop of 0.04% bid and two drops of 0.04% per dose, bid. The systemic exposures are equivalent to 4.2-fold, 7.9-fold, and 13.5-fold the clinical dose, respectively, on a body surface area basis (assuming 100% absorption). Microscopic evaluation of the lungs after 9 months observed pleural/subpleural chronic fibrosis/inflammation in the 0.04% dose male groups, with increasing incidence and severity compared to controls. Lung toxicity was not observed at the 0.024% dose.

Distributed by:

Bausch + Lomb, a division of

Valeant Pharmaceuticals North America LLC

Bridgewater, NJ 08807 USA

U.S. Patent Numbers: 6,211,233; 7,273,946; 7,629,345; 7,910,767; 8,058,467.

VYZULTA is a trademark of Bausch & Lomb Incorporated or its affiliates.

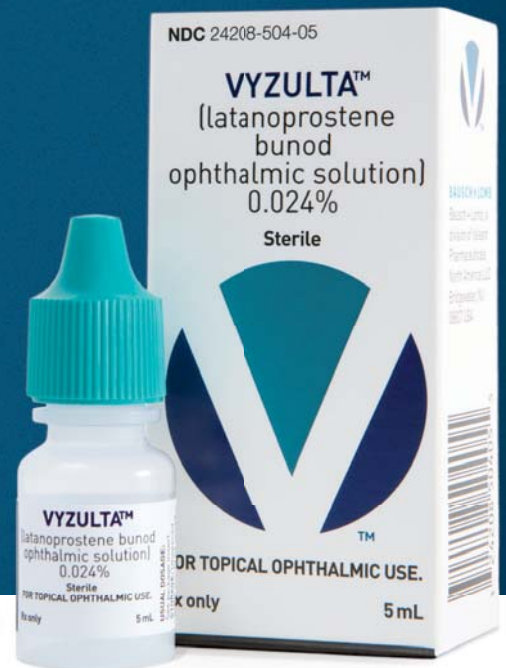© Bausch & Lomb Incorporated

Based on 9464800 11/2017 VYZ.0055.USA.16 Issued: 11/2017

VYZULTA

NOW AVAILABLE

IN PHARMACIES NATIONWIDE



YOU CAN NOW START PRESCRIBING VYZULTA FOR YOUR GLAUCOMA PATIENTS.

- VYZULTA delivers a dual mechanism of action for the reduction of IOP in glaucoma patients¹
- VYZULTA coupons are available for eligible patients
- There is no A/B generic equivalent to VYZULTA. Please share this information with your patients in case they experience a switch at the pharmacy

For more information about VYZULTA, visit vyzultanow.com

INDICATION

VYZULTA™ (latanoprostene bunod ophthalmic solution), 0.024% is indicated for the reduction of intraocular pressure (IOP) in patients with open-angle glaucoma or ocular hypertension.

IMPORTANT SAFETY INFORMATION

- Increased pigmentation of the iris and periorbital tissue (eyelid) can occur. Iris pigmentation is likely to be permanent
- Gradual changes to eyelashes, including increased length, increased thickness, and number of eyelashes, may occur. These changes are usually reversible upon treatment discontinuation
- Use with caution in patients with a history of intraocular inflammation (iritis/uveitis). VYZULTA should generally not be used in patients with active intraocular inflammation

- Macular edema, including cystoid macular edema, has been reported during treatment with prostaglandin analogs. Use with caution in aphakic patients, in pseudophakic patients with a torn posterior lens capsule, or in patients with known risk factors for macular edema
- There have been reports of bacterial keratitis associated with the use of multiple-dose containers of topical ophthalmic products that were inadvertently contaminated by patients
- Contact lenses should be removed prior to the administration of VYZULTA and may be reinserted 15 minutes after administration
- Most common ocular adverse reactions with incidence $\geq 2\%$ are conjunctival hyperemia (6%), eye irritation (4%), eye pain (3%), and instillation site pain (2%)

REFERENCE

1. VYZULTA Prescribing Information. Bausch & Lomb Incorporated. 2017.

BAUSCH + LOMB

VYZULTA and the V design are trademarks of Bausch & Lomb Incorporated or its affiliates.
©2017 Bausch & Lomb Incorporated. All rights reserved. VYZ.0351.USA.17

For more information, please see Brief Summary of Prescribing Information on next page.